



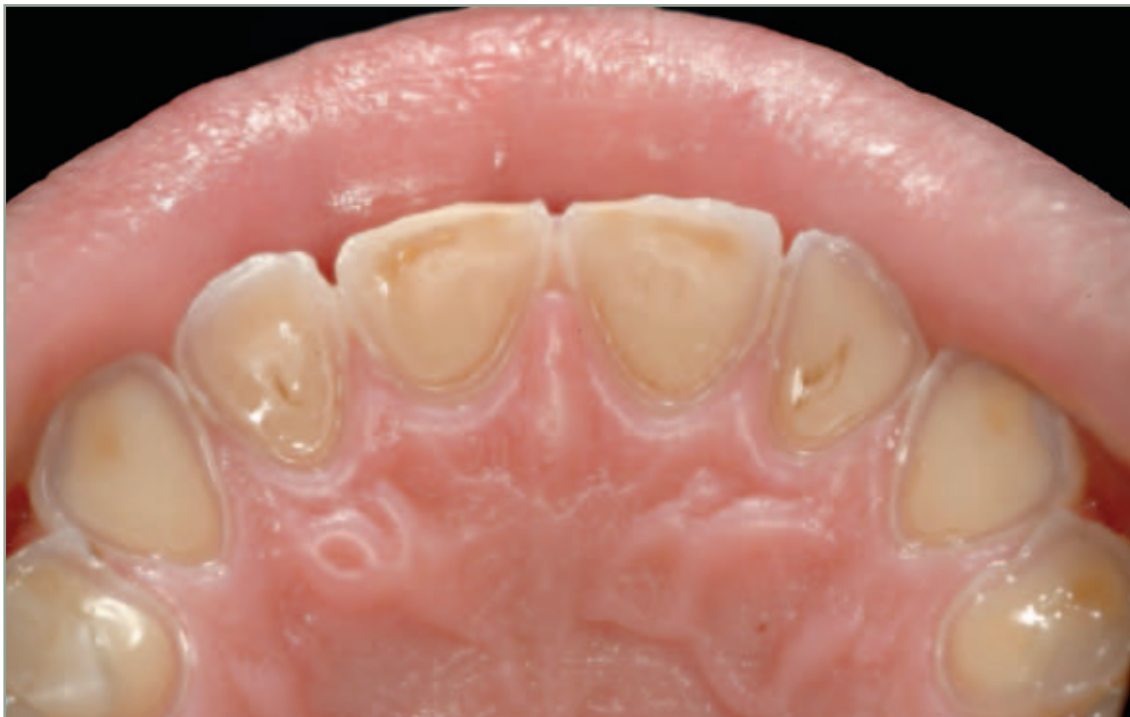# Full-Mouth Adhesive Rehabilitation of a Severely Eroded Dentition: The Three-Step Technique. Part 3.

**Francesca Vailati**, MD, DMD, MSc

Senior Lecturer, Dept of Fixed Prosthodontics and Occlusion  
School of Dental Medicine, University of Geneva, Switzerland  
Private practice, Geneva Dental Studio, Switzerland

**Urs Christoph Belser**, DMD, Prof Dr med dent

Chairman, Dept of Fixed Prosthodontics and Occlusion  
School of Dental Medicine, University of Geneva  
Switzerland



Correspondence to: Dr Francesca Vailati

University of Geneva, Dept of Fixed Prosthodontics and Occlusion, Rue Bathelemy-Menn 19, 1203 Geneva, Switzerland;  
e-mail: Francesca.vailati@medecine.unige.ch.



## Abstract

Dental erosion is a frequently underestimated pathology that nowadays affects an increasing number of younger individuals. Often the advanced tooth destruction is the result of not only a difficult initial diagnosis (e.g. multifactorial etiology of tooth wear), but also a lack of timely intervention.

A clinical trial testing a fully adhesive approach for patients affected by severe dental erosion is underway at the School of Dental Medicine of the University of Geneva. All the patients are systematically and exclusively treated with adhesive techniques, using onlays in the posterior region and a combination of facially bonded porcelain restorations and indirect palatal

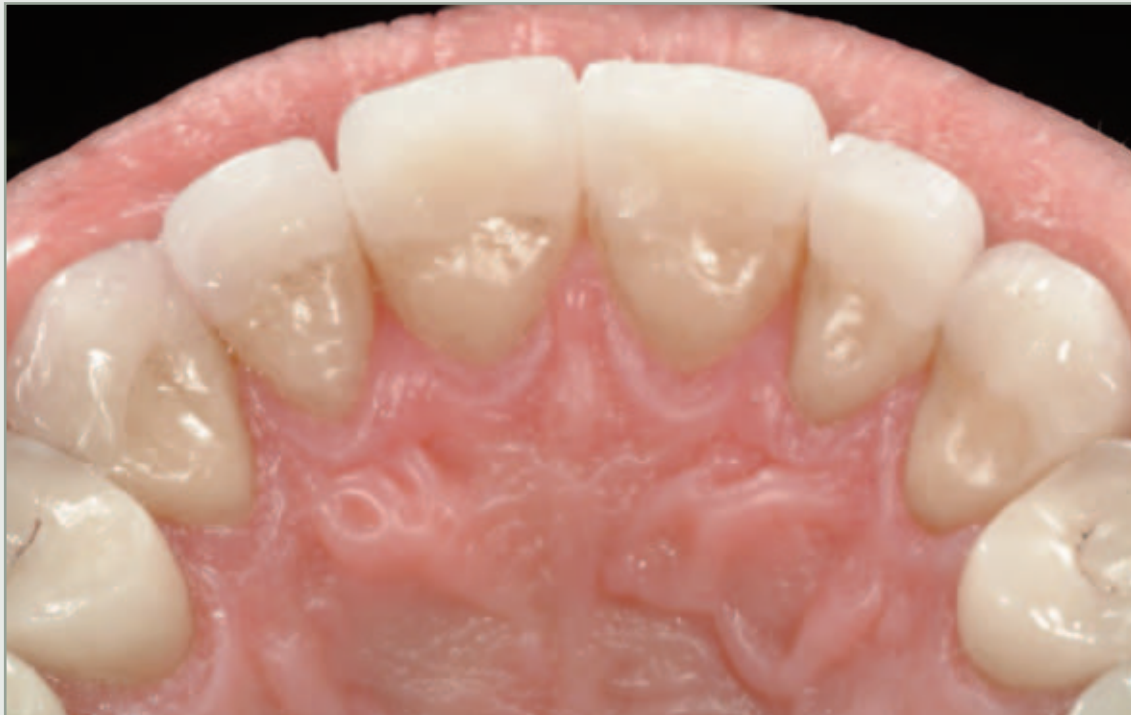resin composite restorations in the anterior maxillary region.


To achieve maximum preservation of tooth structure and predict the most esthetic and functional outcome, an innovative concept has been developed: the three-step technique.

Three laboratory steps are alternated with three clinical steps, allowing the clinician and the dental technician to constantly interact during the planning and execution of a full-mouth adhesive rehabilitation.

In this article, the third and last step of the three-step technique has been described in detail.

*(Eur J Esthet Dent 2008;3:236–257.)*





## Introduction

Patients affected by severe dental erosion often present with an extremely compromised dentition, especially in the anterior maxillary quadrant; the vertical dimension of occlusion may have decreased, and/or and supraeruption of the respective alveolar process segments may have occurred. If erosion is not intercepted at an early stage, full mouth rehabilitation, mostly implementing conventional full coverage (crowns), may be required. Thanks to improved adhesive techniques, the indications for crowns have decreased and a more conservative approach may be proposed to preserve tooth structure, and to postpone more invasive treatments until the patient is older. A clinical trial testing a fully adhesive approach is underway at the School of Dental Medicine at the University of Geneva. All patients affected by generalized advanced dental erosion are systematically and exclusively treated with adhesive techniques, using onlays in the posterior region and a combination of facial bonded porcelain restorations (BPRs) and indirect palatal resin composite restorations in the anterior maxillary region.

As the first and the second steps of the concept have been previously described in detail,<sup>1,2</sup> this article focuses on the third and last step explaining the rationale behind the approach selected to restore the anterior maxillary quadrant.

For better understanding, a brief summary of the two previous steps is presented in the following paragraph.

## First step: maxillary vestibular waxup and the occlusal plane

The first step of the three-step technique is designed to ensure the clinician, the technician and the patient agree on the final treatment objective outcome, before any irreversible therapy starts.

The major goal is to validate the position selected for the plane of occlusion of the final restorations, which is in the authors' opinion the most frequently neglected parameter in a full-mouth rehabilitation.



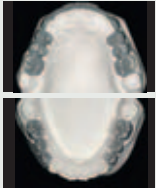



During the first appointment with the patient, photographs, radiographs and alginate impressions are taken (as well as anamnesis and comprehensive clinical examination). Finally, the visit is concluded with a facebow record.

The laboratory technician articulates the two diagnostic casts on a semi-adjustable articulator by the mean of the facebow in the maximum intercuspation position (MIP). As without the clinical validation of the position of the occlusal plane a full-mouth waxup may be useless, the three-step technique proposes that the technician initially waxes up only the vestibular surface of the maxillary teeth. At this time, neither the cingula of the anterior nor the palatal cusps of the posterior maxillary teeth should be included. Inspired by the photographs of the patient, the technician concentrates exclusively on the esthetic appearance of the facial surfaces of the maxillary teeth, with maximum freedom of creativity.

An intermediate clinical step is taken to verify that the direction is correct, and the duplication of the maxillary vestibular waxup by the means of a precisely fitting silicone key concludes the first laboratory step.



**Table 1** The three-step technique.

| Laboratory  |                                   |                              | Clinical  |   |
|---|-----------------------------------|------------------------------|---|---|
|  | Maxillary vestibular waxup        | Step 1:<br>Esthetics         | Assessment of occlusal plane                        |  |
|  | Posterior occlusal waxup          |                              | Creation of posterior occlusion at an increased VDO |  |
|  | Maxillary anterior palatal onlays | Step 3:<br>Anterior guidance | Reestablishment of final anterior guidance          |  |

During the first clinical step, the silicone key is loaded with tooth-colored provisional resin composite and repositioned in the patient's mouth. After its removal, all the buccal surfaces of the maxillary teeth are covered by a thin layer of resin composite that reproduces the defined shape for the future restorations (maxillary vestibular mock-up).

This fully reversible reconstruction of the vestibular cusps of the maxillary posterior teeth and the incisal edges of the anterior teeth allows perfect visualization of both the plane of occlusion and the overall esthetic appearance of the future final restorations.

Other different dental parameters, such as the gingival levels, are also clinically assessed with the full participation of the patient, as described in a previous article.<sup>1</sup>

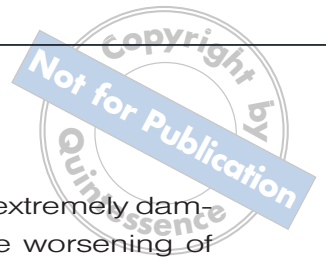
Thanks to the maxillary vestibular mock-up, the patient is reassured at an early stage about the treatment objective, which, in turn, normally means that the patient wishes to immediately begin treatment. With the mock-up in place, new photographs are taken, and the technician can subsequently progress to the second laboratory step.

## Second step: posterior occlusal waxup and new occlusion at an increased vertical dimension of occlusion

The second laboratory step deals with the posterior occlusion, as at this stage, the waxup only involves the posterior quadrants of both the maxillary and mandibular casts.

In case of a severely eroded dentition, an increase of the vertical dimension of occlusion (VDO) is inevitable in order to reduce the need for substantial tooth preparation in general and to avoid the necessity of elective endodontic treatments in particular.

For each patient, the new VDO is decided arbitrarily on the articulator, taking into consideration both the posterior teeth, where the maximum feasible increase is desirable to maintain a maximum of mineralized tissue, and the anterior teeth, which should not be set too far apart as this would jeopardize the reestablishment of anterior interarch contacts and the related anterior guidance. As the new VDO should



always be tested clinically prior to its final acceptance before any irreversible treatment starts, the second step is devoted to testing that the patient can adapt to the new therapeutic occlusion.

As explained in the authors' previous article<sup>2</sup>, the laboratory technician will wax up only the two premolars and the first molar in each sextant to recreate the occlusal scheme planned for the final restorations.<sup>2</sup>

Four translucent silicone keys are then fabricated, each duplicating the waxup of one posterior quadrant. The patient is subsequently scheduled for a next appointment. This time the clinician explains that another reversible treatment will be performed. However, this will change the occlusion of the patient.

The translucent keys are loaded with resin composite prior to placement in the patient's mouth. Thanks to the described translucency, a light-curing resin composite can be utilized.

Without any tooth preparation (only etching and bonding), the occlusal surface of all the premolars and the first molars are restored with a layer of resin composite, reproducing the respective diagnostic waxup.

The three-step technique recommends an arbitrary observation period of approximately 1 month to assess the patient's adaptation to the newly established VDO. The new occlusion obtained is peculiar in that the anterior teeth are no longer in contact. The degree of this transitional open bite depends on the one hand on the amount of increase of VDO required, and on the other hand on the patient's original vertical overlap and the severity of the incisal edge destruction.

Patients should be informed that the esthetic appearance of their smile could worsen at this transitional stage of therapy,

especially in the case of an extremely damaged anterior dentition. The worsening of their smile is due to the fact that the maxillary posterior teeth have been lengthened by the posterior provisional resin composites, whereas the maxillary incisal edges have not yet been restored (Fig 1).

Some speech impairments can also be expected, as the anterior teeth are set apart and more air can escape during the pronunciation of the letter 's'. However, patients are generally so motivated after the first clinical step that they do not find this treatment phase particularly stressful or unbearable. The second clinical step has been conceived to simplify the clinician's work, without compromising the final outcome of the full-mouth rehabilitation.

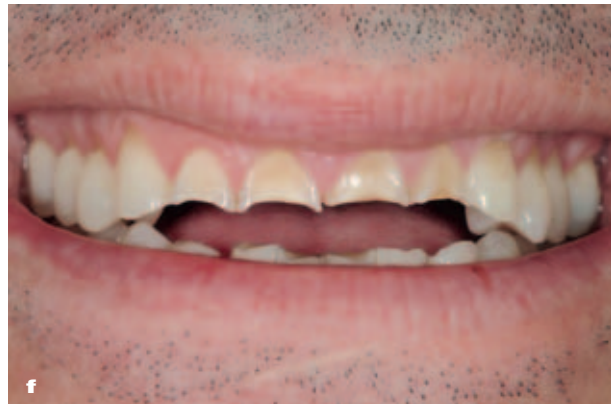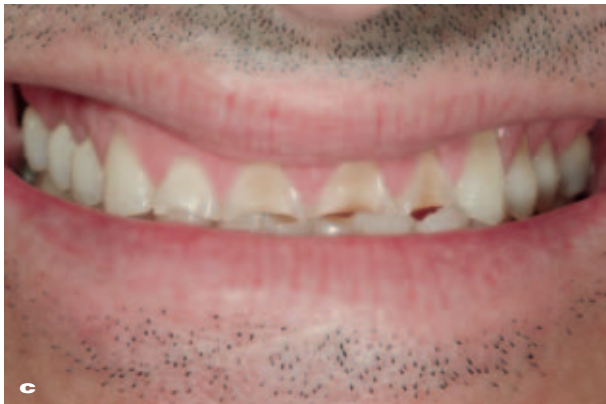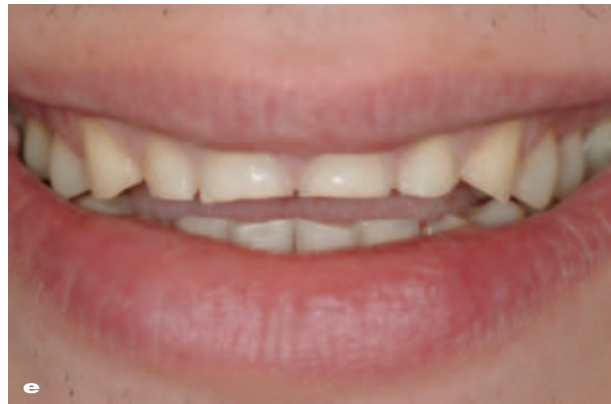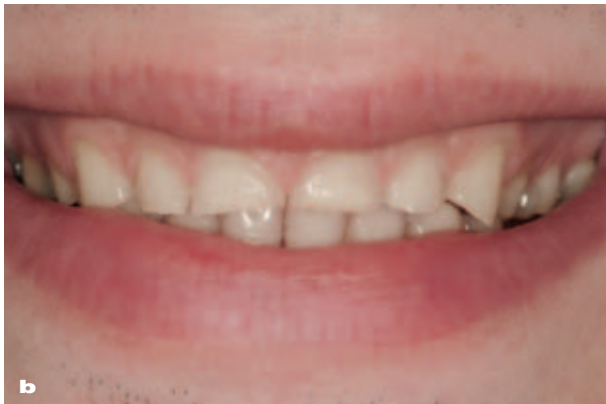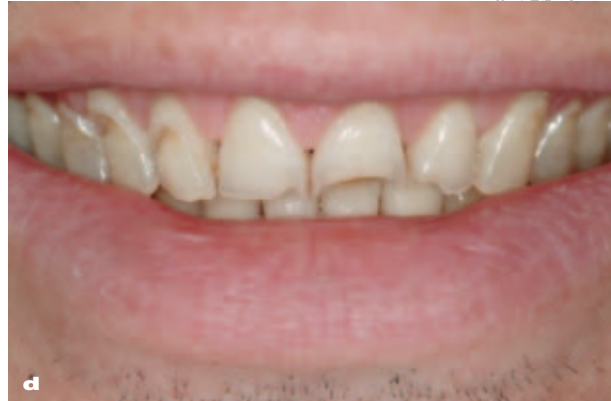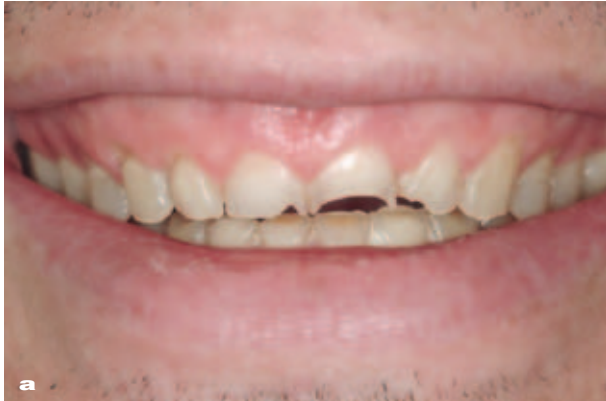Consequently, it was decided for all patients not to attempt to simultaneously restore the anterior teeth while restoring the posterior quadrant with provisionals.

As previously mentioned, thanks to the maxillary mock-up of the first clinical step, patients are very trusting, as the planned treatment objective has been visualized and thoroughly explained beforehand. Consequently, this transitional period is accepted without major complaints, and none of the patients enrolled in our study requested an earlier reconstruction of the anterior teeth. The most frequent objection raised by colleague clinicians to this technique is that without adequate anterior guidance, a new occlusion at an increased VDO cannot be correctly assessed. However, to date, there is no robust scientific evidence available to support this criticism. In the authors' experience, patients are able to function well for a short period of time without anterior contacts.

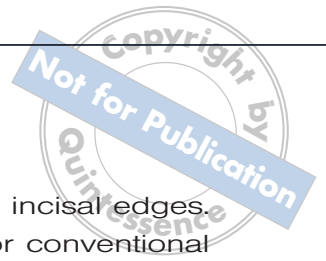Finally, according to the three-step technique, all these patients enrolled for thera-



Not for Publication



**Fig 1a to f** Three patients before treatment (**left**) and at completion of the second clinical step (**right**). As the anterior teeth have not been restored at this stage patients lose anterior guidance and the esthetic appearance is worsened. The more compromised the anterior teeth are, the more visible the reverse smile will get. However, normally, patients do react very well to this transitional stage, as they undertook the mock-up session and, thus, were reassured when it comes to the perspective of the planned final result of treatment.



py should undergo a consultation with a specialist in the field of temporomandibular disorders prior to initiating treatment, in order to assess the clinical status of their articulations.

As the second clinical step (provisional posterior resin composites) is considered fully reversible, the transient occlusal resin composite restorations can be easily modified or completely removed from the unprepared posterior teeth if signs and/or symptoms of temporomandibular dysfunction should arise.

### Third step: the anterior guidance

At the completion of the second step, a stable posterior occlusal support is established. As mentioned previously, owing to the presence of the posterior provisional resin composites, the anterior teeth are set apart. Consequently, the third and final step of the three-step technique deals with the restoration of the anterior quadrants (reestablishment of an adequate, functional permanent anterior guidance).

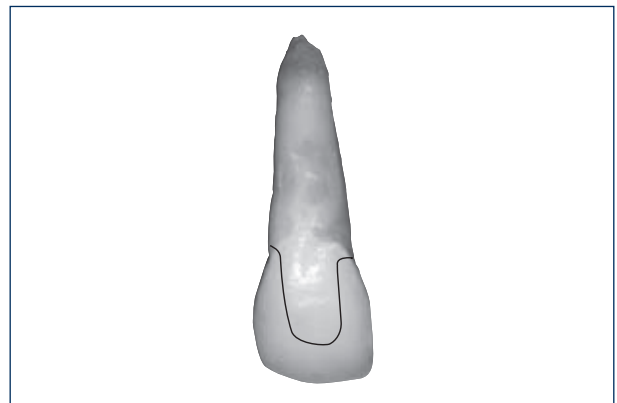### Restoration of the maxillary anterior teeth, a minimally invasive treatment: the 'sandwich approach'

Generally, the palatal aspect of the maxillary anterior teeth is severely affected by the destructive combination of erosion and attrition, which leads to a substantial loss of tooth structure. After the loss of enamel, the exposed dentin is subject to accelerated wear, which leads to a pronounced concave morphology, and frequently, to weak-

ening and fracturing of the incisal edges. Following the guidelines for conventional oral rehabilitation concepts, such structurally compromised teeth should receive full crown coverage. In order to place the crown margins at the gingival level, the entire coronal tooth structure, mesially and distally, is removed to guarantee the path of insertion of the crown (see Fig 2).

The entire facial aspect will also be substantially reduced in the process of preparing the 1.5 mm shoulder ceramic margins for porcelain-fused-to-metal crowns. Even when the more conservative all-ceramic crowns are adopted (eventually <1 mm of chamfer preparation) the clinician still has to eliminate the mesial and distal undercuts of the tooth and smoothen the sharp edges, leading to a highly invasive preparation of the axial walls.

Several studies have demonstrated the importance of the marginal ridges for posterior teeth. Restorations that extend to the



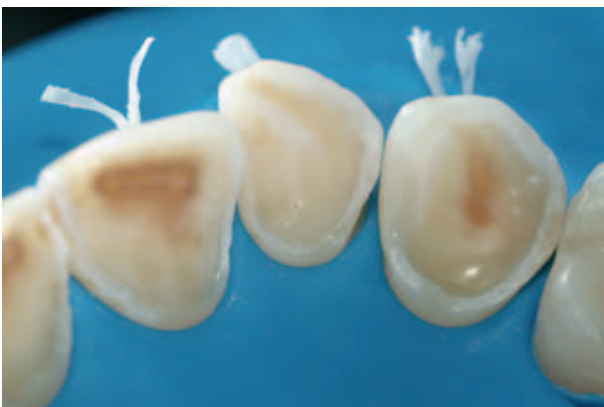
**Fig 2** Maxillary incisors are chisel-shaped teeth. In order to remove the retentive areas and to prepare margin of at least 1 mm circumferentially, crown preparation cannot be considered conservative. Only veneer preparation can guarantee to preserve the triangular shape of these teeth, thanks to the facial insertion path of the restoration.<sup>3</sup>



mesial and distal aspect, such as a MOD restoration, greatly affect the strength of the restored posterior teeth.<sup>4-6</sup>

In the authors' opinion, the mesial and distal marginal ridges of the anterior teeth may have a similar importance as described for posterior teeth in guaranteeing structural strength, thus, representing a framework for enamel. Therefore, the removal of these mesial and distal marginal ridges of the anterior teeth could dramatically compromise the tooth flexibility (the "tennis racket theory"), see Fig 3. Preparing such teeth for crowns will complete the destruction initiated by the erosive process. Not infrequently, elective endodontic treatment will be necessary, and posts will then be used to assure retention of the final crowns.

Only a few articles have been published that have aimed at investigating the survival rate of single crowns on vital natural teeth, and there are no long-term follow-up studies on the survival of devitalized and



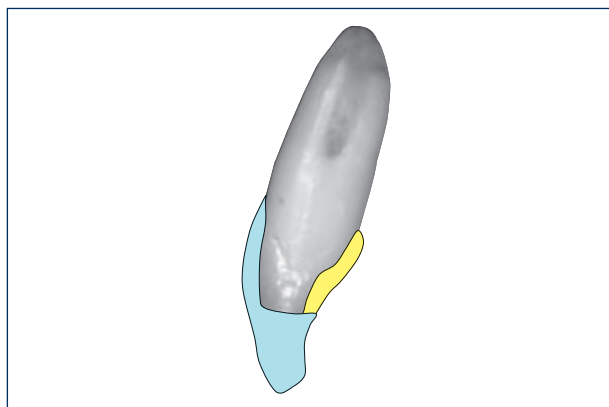
**Fig 3** Even though these teeth have been severely structurally compromised, the enamel layer representing the remainder of the mesial and distal marginal ridges is still visible. Like the external frame of a tennis racket, these bands of enamel may play a significant role in strengthening the tooth (the "tennis racket theory").

crowned teeth in very young patients.<sup>7-14</sup> However, the problems that arise when a tooth loses its vitality, such as periapical lesions, discolorations, root fractures, etc. are well documented.<sup>15-17</sup>

To avoid aggressive treatments on the one hand and to keep teeth vital on the other hand, an experimental approach of restoring the maxillary anterior teeth of patients affected by severe dental erosion is currently under investigation at the University of Geneva, School of Dental Medicine.

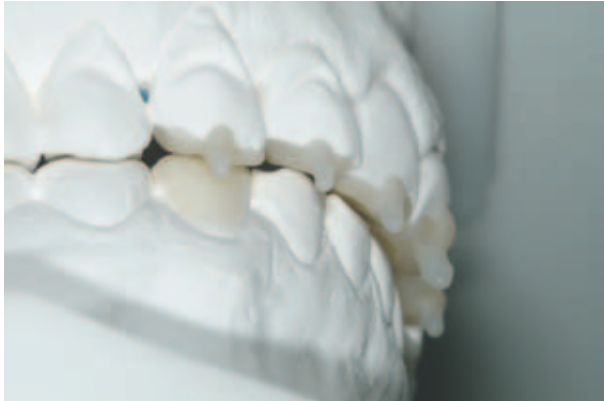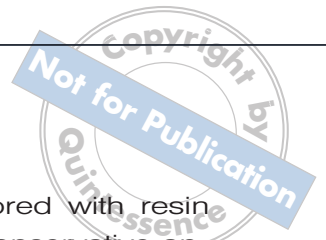The authors' minimally invasive treatment concept consists of reconstructing the palatal aspect with resin composite (direct or indirect, as will be explained later in this article)<sup>18-19</sup> and to restore the facial aspect with ceramic veneers.

The final outcome is reached by the most conservative approach possible, as the remaining tooth structure is preserved and located in the center between two different restorations (the sandwich approach) (Fig 4).



**Fig 4** The sandwich approach. Keeping tooth preparation minimal, the remaining tooth structure of the eroded maxillary anterior teeth is maintained in between two adhesive restorations, performed at two different moments in time, i.e. first the palatal resin composite and second the facial ceramic veneer.





**Fig 5** At the completion of the second step, the patient has a stable posterior occlusion. To reconstruct the palatal aspect of the maxillary anterior teeth before restoring them with veneers, the clinician can select direct or indirect resin composites. In this specific case, indirect resin composite restorations were preferred, as it was judged that the interocclusal space was conspicuous and that the anterior guidance could have been better recreated in the laboratory.

A still experimental, but highly promising, ultra-conservative approach, implementing both basic principles of biomimetics and adhesive technology, has recently been published by Magne et al.<sup>20-23</sup>

Severely compromised anterior teeth have been restored without following the classic rules of crown preparation, which traditionally would require localization of the restoration margins on sound tooth structure.

To the contrary, teeth with extensive class 3 defects were directly restored with adhesive resin composite restorations before the facial veneer preparations were performed, treating the resin composite as an integral part of the tooth. In other terms, a part of the veneer margins were located on resin composite. Along these lines the three-step technique has pushed the limit of this innovative application, as the teeth to be restored with facial ceramic veneers had previously the

entire palatal surface restored with resin composite. Such an ultra-conservative approach cannot be matched by any type of full-crown preparation.

For all patients involved in this prospective clinical study, a strict follow-up is scheduled to collect information on the survival and eventually complication rates of such novel anterior restorations. The detailed protocol and the preliminary results of the study will be the topic of another article.

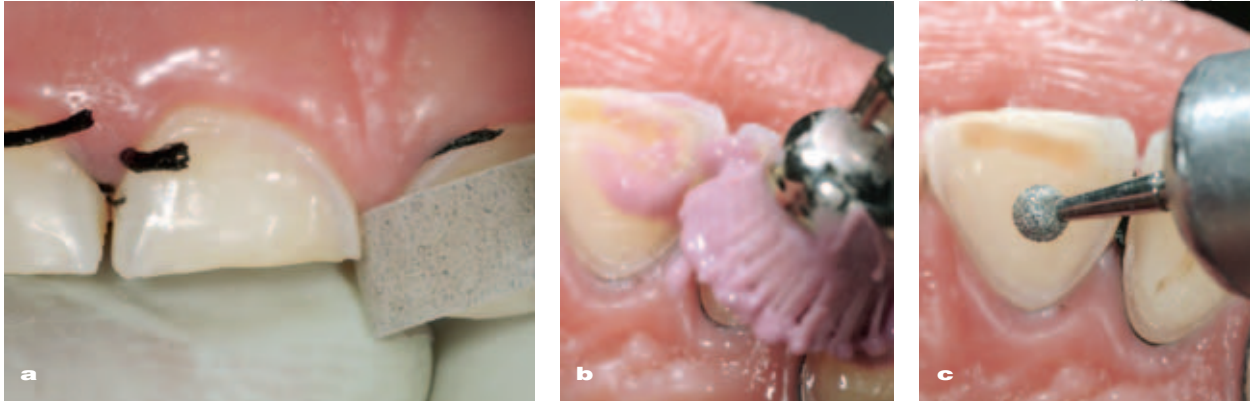
### Palatal aspect: direct or indirect resin composites?

After 1 month of functioning with the posterior occlusal interim resin composite restorations, it is assessed whether or not the patient feels comfortable with the new occlusion. Subsequently, two alginate impressions and a new facebow record are taken. In order to mount the casts in MIP, an anterior occlusal bite registration is also required.

The laboratory technician verifies on the mounted casts that the second step had been accurately executed. In other words, he/she must check that the position of the occlusal plane is actually located where it was planned, and that the posterior teeth with the provisional resin composites look similar to the original waxup. Thanks to the presence of the non-restored second molars, a precise verification of the amount of increase of VDO is possible at any time.

The type of restoration that is best indicated to restore the palatal aspect of the maxillary anterior teeth (i.e. direct or indirect resin composite) is then selected, Fig 5.

If the space is reduced (<1 mm), the resin composites can be done directly free-hand, saving time and money (there



**Fig 6a to c** Palatal onlay preparation. The only tooth preparation required is the slight opening of the interproximal contacts, to provide the laboratory technician access during trimming of the dyes on the master cast. The dentin will be subsequently cleaned, followed by removing the most superficial layer with a diamond bur. Note that, due to the erosive process, a cervical chamfer-like preparation is already present.

is no laboratory fee for the palatal onlays and only one clinical appointment is required). If the interocclusal distance between the anterior teeth is, instead, significant, free-hand resin composites could prove to be very challenging.

When the teeth present a combination of compromised palatal, incisal and facial aspects, it is difficult to visualize the optimal final morphology of the teeth, particularly while restoring at this stage only the palatal side with rubber dam in place. Thus, the result may be unpredictable and highly time consuming.

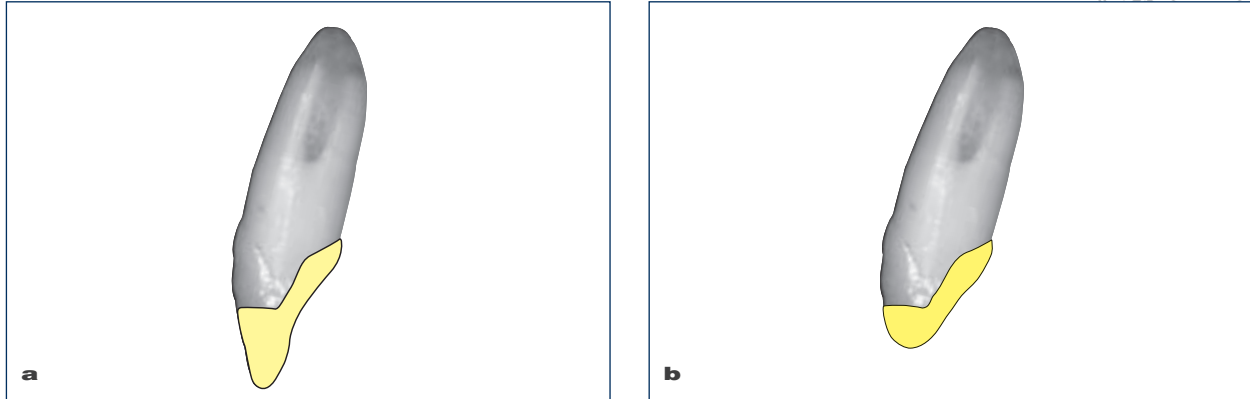
Under such conditions, fabricating the palatal onlays in the laboratory clearly presents some advantages, including superior wear resistance and higher precision during the creation of the final form.<sup>24</sup>

## Palatal onlays: tooth preparation

In case the indirect approach is selected, the clinician will schedule an appointment to proceed to the preparation for the

palatal onlays of the six maxillary anterior teeth. This preparation can be a quite an easy and rapid procedure. In fact, in the case of severe dental erosion, the palatal aspect of the maxillary anterior teeth is generally the most affected of the entire dentition. Under the described circumstances, the erosion and the attrition processes have already created the space necessary for the onlays, and no additional tooth preparation is required once an anterior tooth separation is generated by the increase of VDO.

In addition, at closer observation, the cervical part next to the gingiva frequently presents a chamfer-like preparation configuration, with a small band of enamel still present. Owing to the buffering action of both the sulcular fluid and the plaque, this thin layer of enamel is often preserved from the acid attack and its presence will provide a superior quality of adhesion. As this chamfer is located supragingivally and there is no need to extend the margins subgingivally, the next restorative steps are also facilitated (e.g. impression-taking and bonding of the final restorations).



**Fig 7a and b** During the fabrication of the palatal resin composites, the technician and the clinician can decide to reestablish the full length of the future veneers or to keep the incisal edges slightly shorter.

The only features required are to slightly open the interproximal contacts between the maxillary anterior teeth by means of stripping and to smoothen the incisal edges by removing unsupported enamel prisms. The palatal dentin is also cleaned with a non-fluoride-containing pumice, and the most superficial layer removed with appropriate diamond burs (Fig 6).

Owing to this minimal tooth preparation, sensitivity does not develop. Consequently, no provisional restorations are required during the time necessary for the laboratory technician to fabricate the palatal onlays. After the final impression, the appointment is concluded with an anterior bite registration of the patient's maximum intercuspitation position.

### Third laboratory step: the fabrication of the palatal onlays

The maxillary master cast comprising the preparations for the palatal onlays is mounted on the articulator in MIP. Another facebow record is not necessary at this

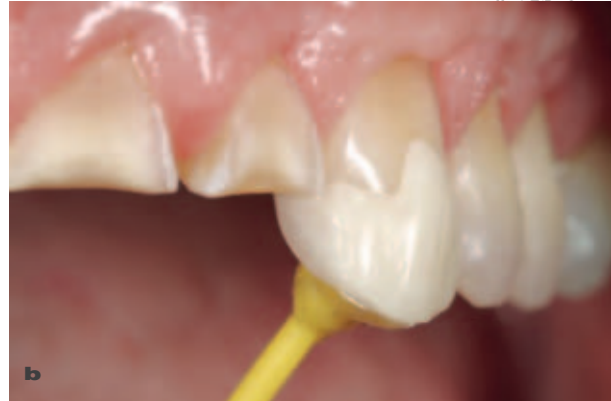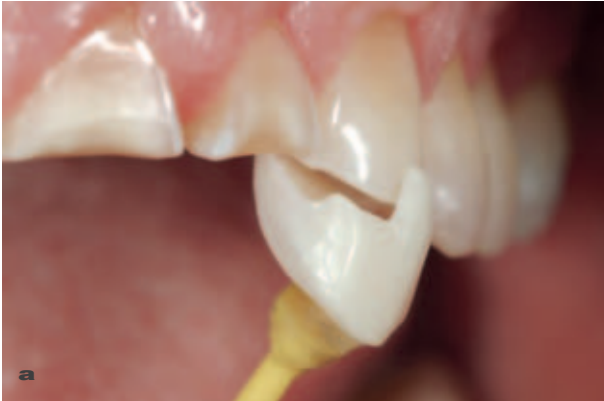stage, as the information on how to orientate the casts to the hinge axis of the articulator is preserved by the previously mounted mandibular cast.

As the interproximal contacts have been removed before taking the impression, the maxillary anterior teeth are already slightly separated from each other on the working cast, facilitating the trimming of the dyes.

The laboratory technician is specifically instructed to focus on the shape of the palatal onlays in view of:

1. Establishment of an adequate functional anterior guidance
2. Optimization of the future transition between the palatal onlay and the veneer.

At this stage, the laboratory technician can either directly fabricate the palatal onlays, or decide to wax up completely the maxillary anterior teeth in order to better visualize the future junction between the palatal onlay and its corresponding facial veneer. This is a demanding step, and each laboratory technician, who has participated so far in this project, has selected a slightly different approach.



**Fig 8a and b** To facilitate the positioning during bonding of the palatal onlays, a small hook is fabricated. This incisal stop will be removed easily during finishing and polishing. Note that in this patient the decision to restore the full length of the teeth with the palatal resin composites was made.

During the fabrication of the palatal resin composites, the technician and the clinician can decide to reestablish the final length of the future veneers or to keep the incisal edges slightly shorter (Fig 7).

In case of severe dental erosion, the facial aspect of the maxillary teeth may also be significantly involved and the layer of enamel thinned, to the point that the teeth appear more yellow – the dentin itself, exposed at the level of the incisal edges, could also be stained. Consequently, patients with advanced dental erosion frequently complain about the color of their teeth, becoming victims – like many other people – of the bleaching obsession of modern times. If one has decided to increase the length of the teeth before the fabrication of the facial veneers by means of the palatal onlays, patients should be informed that there may be a possible color mismatch with the vestibular surfaces. The color of the palatal onlays will be different, as it is meant to match the color of the final veneers, instead of the unrestored facial aspect of the teeth.

Generally, patients are so happy to have their anterior teeth lengthened that

they do not consider this as a major drawback.

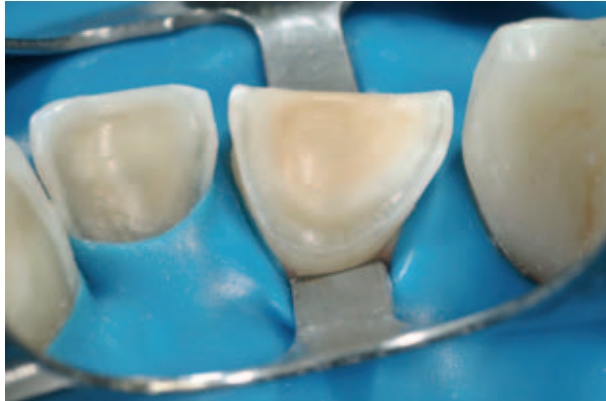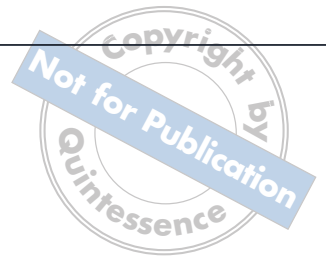It is very important that the laboratory technician fabricates a kind of hook at the level of the incisal edge (incisal stop), made of the same material as the restoration, which will help to position and stabilize the onlay during the bonding procedure (Fig 8).

### Third clinical step: reestablishment of anterior contacts and the anterior guidance

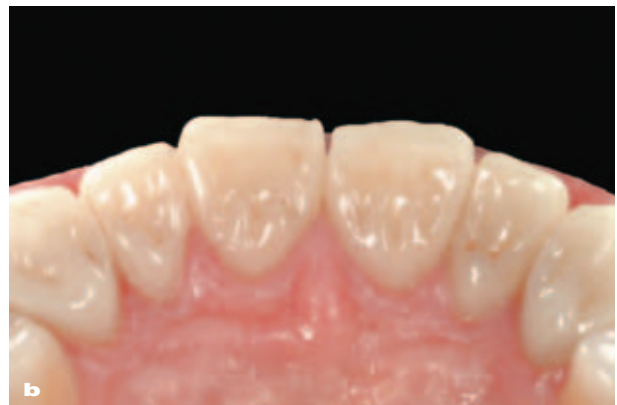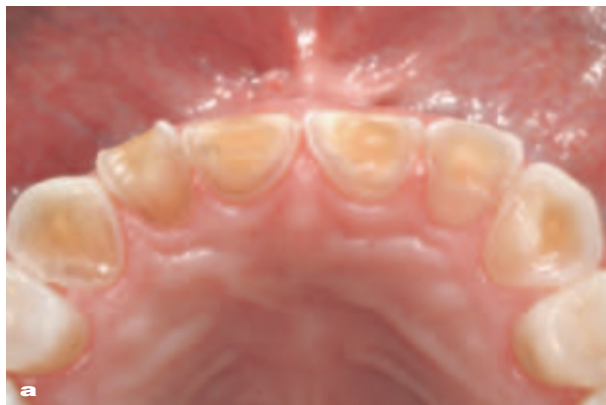When an indirect approach is selected, an additional appointment is necessary to deliver the final palatal restorations.

Whereas tooth preparation and final impression for indirect palatal resin composites are simple procedures, bonding of these restorations may be a demanding step, not only for the more difficult visibility of the operating field, but because of the necessity to guarantee moisture control.

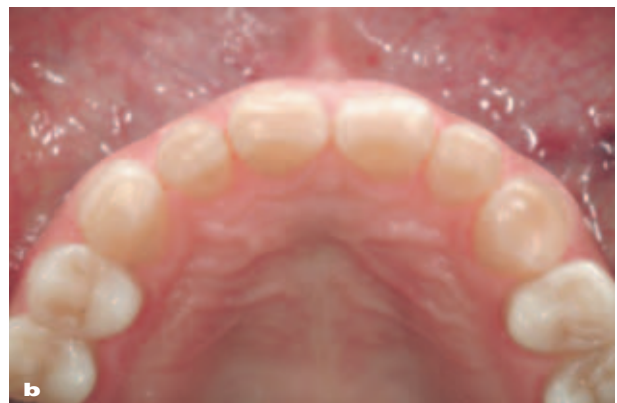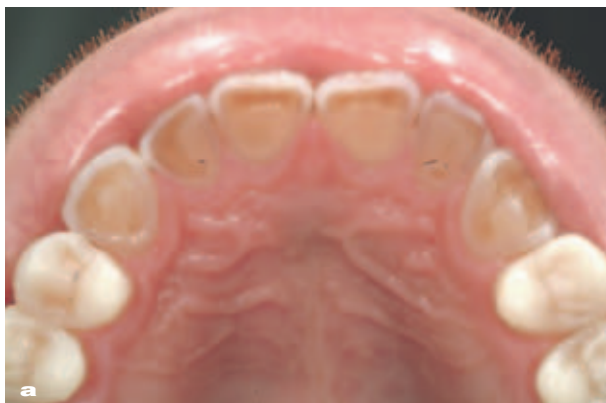The posterior resin composites are provisional restorations and, thus, the use



**Fig 9** Bonding procedure of a palatal onlay. The use of rubber dam is crucial. To expose the margin it is necessary to place a clasp on the tooth receiving the onlay. Once the bonding of the restoration completed, the clinician will remove the clasp and place it on the adjacent tooth to bond the next onlay.



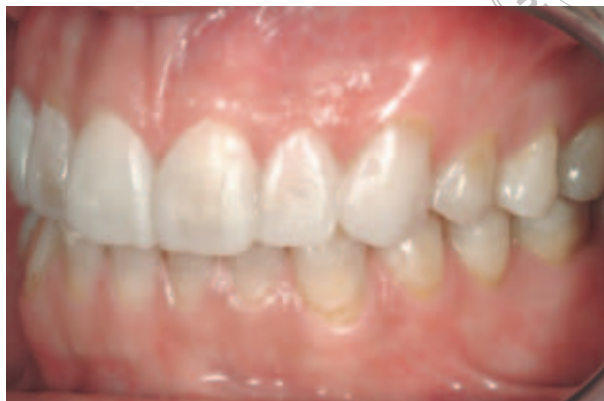**Fig 10a and b** Third clinical step. Clinical close-up views before and after bonding of six palatal resin composite onlays. In this patient, the full length of the future veneers was reconstructed at this intermediate stage of therapy by means of palatal onlays. This approach is clearly more demanding for the laboratory technician, see Fig 7a.



**Fig 11a and b** Third clinical step. Clinical close-up views before and after bonding of six palatal resin composite onlays. In this patient the resulting orofacial dimension of the restored teeth seems unnaturally larger. This is due to the fact that the teeth were not restored to their final length at this stage in the treatment, see Fig 7b.



**Fig 12** At completion of the third step, the patient is scheduled for final diagnostic mock-up, which this time will involve only the six maxillary anterior teeth. The waxup of these teeth and the subsequent mock-up are necessary steps, not only to confirm the final shape of the veneers, but also to produce the silicone keys guiding the veneer preparations and serving as template for the provisional restorations



of rubber dam is not necessary, whereas the palatal onlays are final restorations and the bonding conditions should be optimal.

To ensure the best conditions for the adhesive procedures, after the placement of rubber dam, every onlay is bonded once at the time using hybrid resin composite (e.g. Miris, Coltène/Whaledent), following the protocol proposed by P. Magne for ceramic veneers. The only difference is that the intaglio surface of the resin composite palatal onlays is microsandblasted (30  $\mu\text{m}$  Cojet sand, 3M Espe), and not treated with fluoridic acid. To correctly isolate the margins, it is necessary to place a clamp on the tooth receiving the onlay, otherwise the rubber dam would overlap the margins (Fig 9).

Considering that the substrate is mostly sclerotic dentin, and that the length of the final restorations is sometimes double of the original length of the remaining tooth structure, the task requested for the bonding is major.

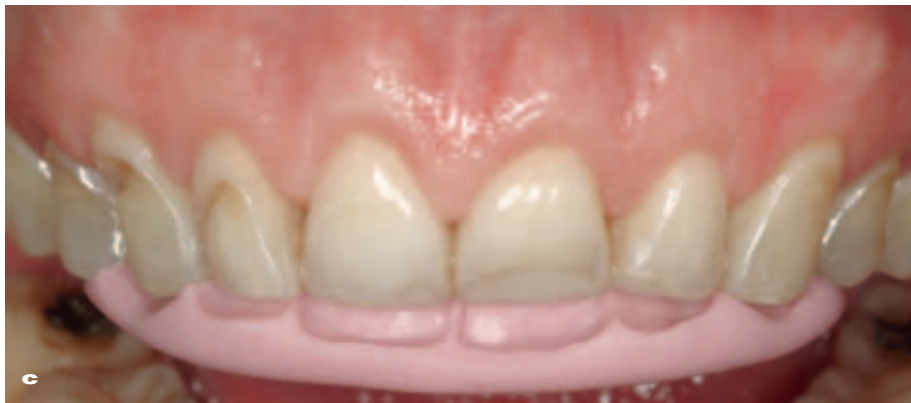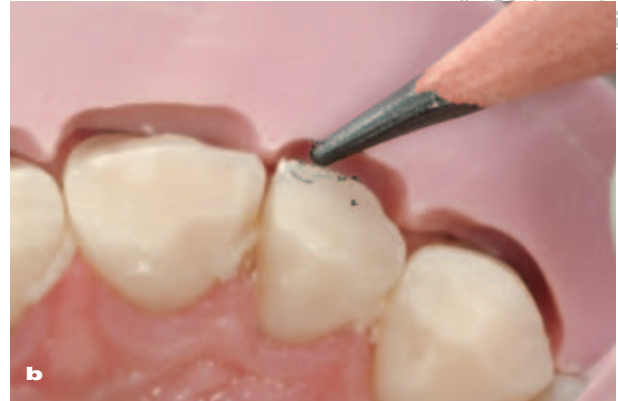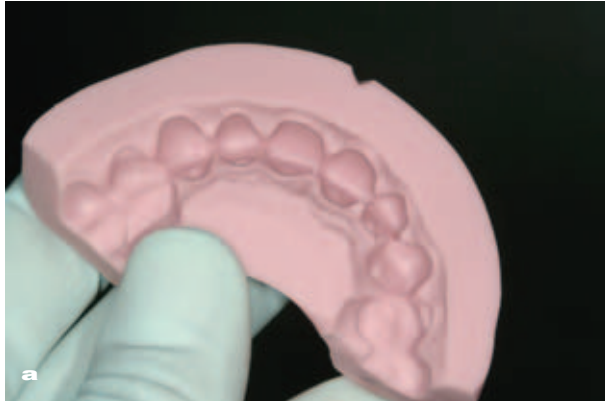
Success can only be ensured by optimal bonding conditions on the one hand and by the presence of enamel at all margins of each onlay, except, of course, at the incisal level.

Once the tooth is isolated by means of rubber dam, the bonding procedure itself is not complicated, as the incisal stops help to position the palatal onlays, the interproximal contact points are often not a concern, and the margins are supragingival (Figs 10 and 11).

### Facial aspect: ceramic veneers

The restoration of the palatal aspect of the maxillary anterior teeth concludes the three-step technique. At this stage, the patient has reached completely stable occlusal conditions (in the anterior and posterior quadrants) so the clinician can decide, without pressure, on the pace to adopt for the completion of therapy and on the type of restorations. Generally, the mandibular anterior teeth only need minor treatment and can, in most instances, be restored with direct resin composites.

Before replacing the posterior provisional resin composite restorations with ceramic or resin composite onlays, it is preferable to complete the restoration of the facial aspect of the maxillary anterior teeth.



**Fig 13a to c** Three silicone keys are obtained from the waxup of the six anterior maxillary teeth: one for the mock-up, another for the facial reduction and a third one for the incisal reduction. The index for the mock-up will be used again after tooth preparation of the veneers, to fabricate the provisional restorations.

As the protocol followed at the University of Geneva previews facial ceramic veneers to be the permanent restorations, a second mock-up of the six maxillary anterior teeth is recommended (Fig 12).

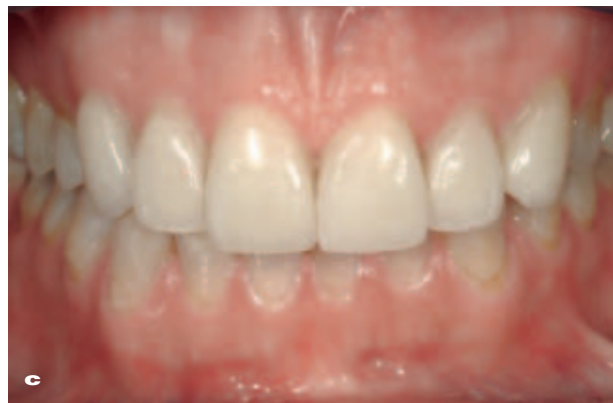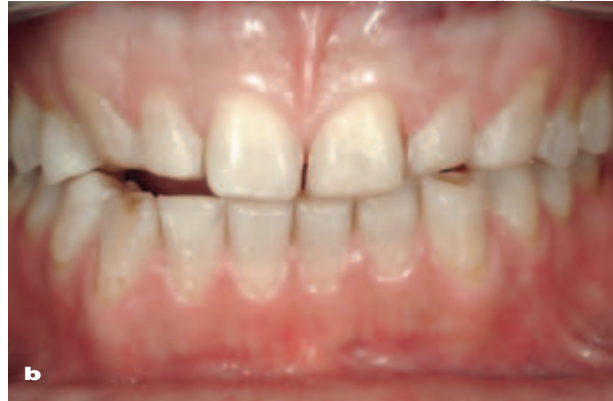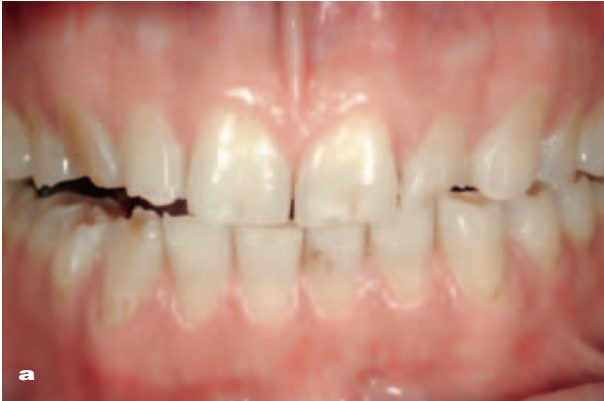While waxing up, the technician should be guided by the maxillary vestibular mock-up done at the beginning of the three-step technique, and adapt it to the new occlusion of the patient.

As the position of the occlusal plane and the increase of VDO may be slightly different from what was initially planned, the length of the maxillary anterior teeth should be reconfirmed during the second mock-up session.

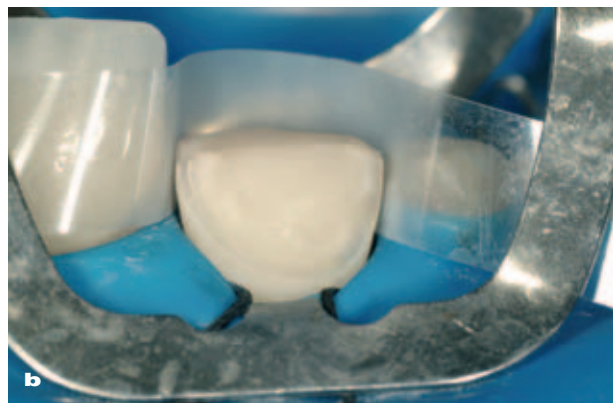
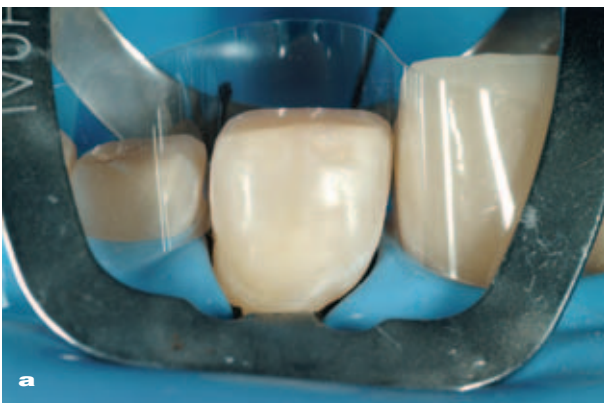If the patient's consensus on the final shape of the maxillary anterior teeth is obtained, another two silicone indexes are fabricated based on the waxup, to guide the clinician during veneer preparation (reduction keys) (see Fig 13).<sup>25-31</sup>

The veneer preparation follows standard protocols developed and described in detail by other authors (Fig 14).<sup>24-30</sup>

The only difference between this novel concept and a more traditional veneer approach is that the palatal aspects of the maxillary anterior teeth are considered as integral part of the respective teeth and no particular effort is made to place the preparation margins for the veneers on tooth structure. In addition, the

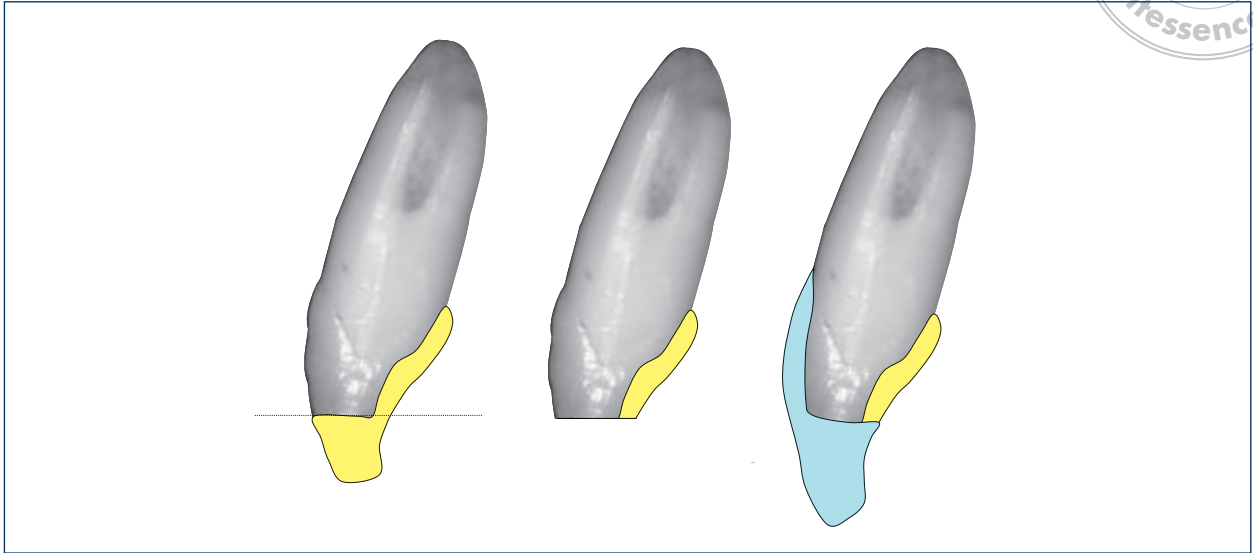
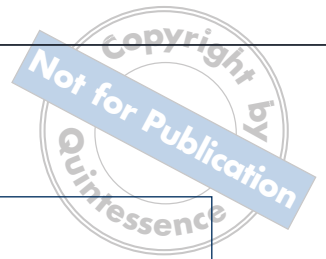


**Fig 14a to c** Initial clinical view of a 27-year-old male patient before and after bonding of six maxillary anterior ceramic veneers. Note both the gingival health and the minimal tooth preparation. The rehabilitation has been performed according to the principles of the three-step concept. The next step will involve the replacement of the posterior provisional resin composites.

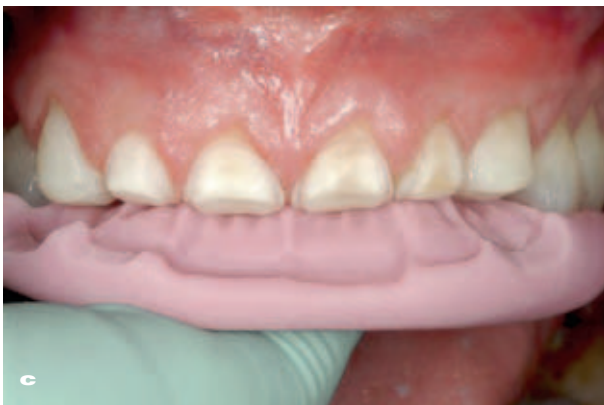
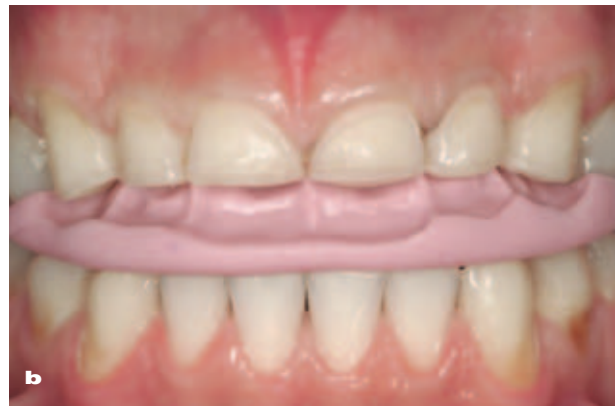
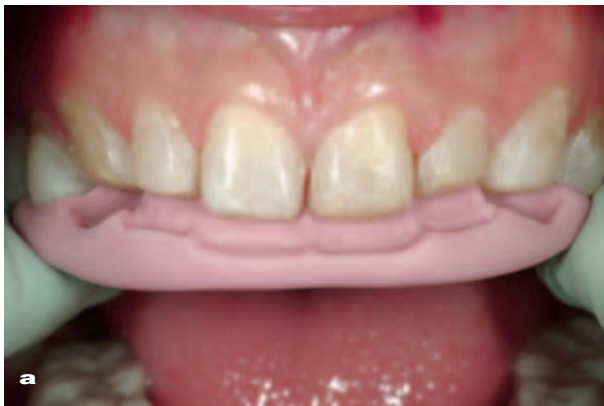**Fig 15a and b** Two different typical clinical situations during the bonding procedure of the facial veneers. Note that in Fig 15a the facial enamel has been preserved. However, in Fig 15b the erosive process had greatly affected the facial aspect of the tooth.





**Fig 16** Schematic drawing of the recommended preparation for the veneers at the level of the incisal edges. The length added by the palatal onlay is completely removed. The ceramic veneer will later reestablish the final length.



**Fig 17a to c** Three different patients after veneer preparation with the silicone key in place reproducing the length of the final veneers. Following the protocol of the University of Geneva, all the tooth-length added by the palatal resin composites had to be removed.



Not for Publication  
Quintessence

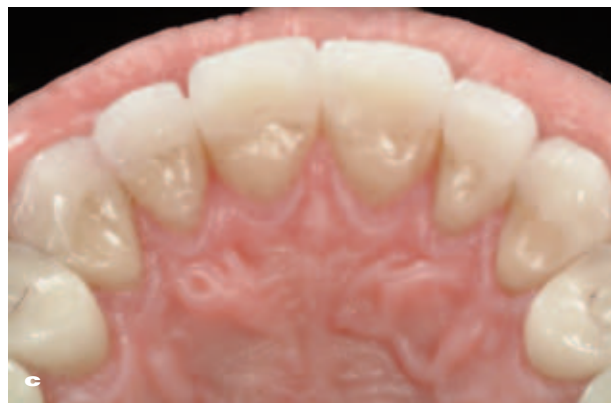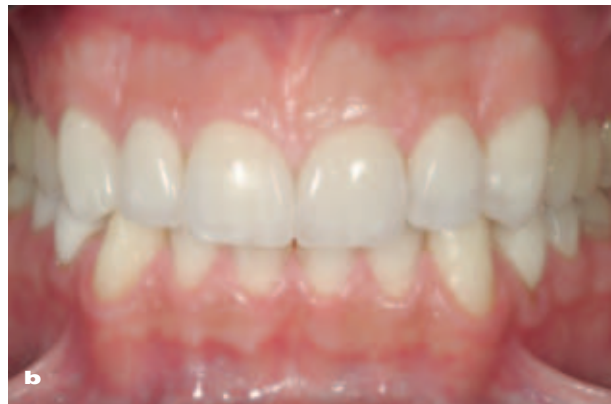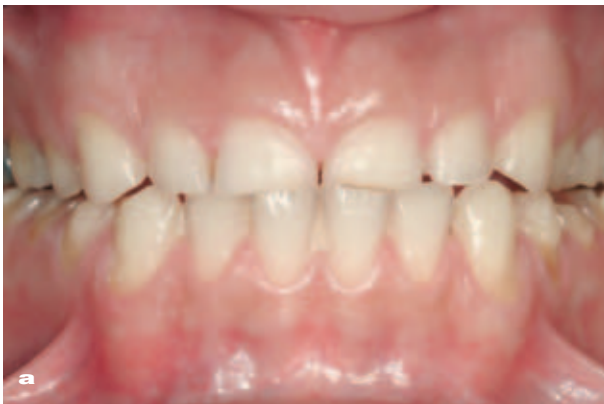described concept comprises an incisal coverage in form of a butt joint, with the ceramic veneer margin placed in the volume of the palatal resin composite onlays (see Fig 15).<sup>32</sup>

In a situation where the incisal length of the maxillary anterior teeth is severely reduced and the respective tooth volume has been subsequently reestablished by means of palatal onlays, the decision has to be made whether or not to remove the entire length added with the resin composite or to leave part of it before restoring the teeth with the facial veneers.

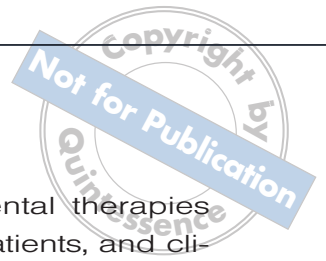The authors' preference is to completely remove the length added by the palatal onlays, leaving only the original length of the tooth on the facial aspect (Fig 16). The

rationale for this approach is to avoid placing the margin of the veneers in the palatal concavity of the tooth, by moving it more cervically (Fig 15).<sup>33</sup> In addition, without the layer of resin composite, the veneer fabrication is facilitated, as there is a more uniform color on the facial surface.

Even in patients where almost three quarters of the original tooth length is missing, the guidelines preview not to preserve some of the length of the palatal onlay (Figs 16 and 17). As the sandwich approach is still experimental, a strict follow up of all these types of restorations is applied. By means of photos and impressions the interface between the facial veneers and the palatal resin composite onlays is carefully evaluated. Time will show



**Fig 18a to c** The two year follow-up of a patient treated following the sandwich approach for the maxillary anterior teeth demonstrated very encouraging results. The gingival health is remarkable, and all the teeth are still vital.



if problems may arise. However, the initial data collected seemed very promising (Fig 18).

After bonding of the maxillary anterior veneers, the rehabilitation can progress with the replacement of the posterior provisional resin composites.

In fact, owing to the presence of a functional anterior guidance and optimized posterior support, the full-mouth rehabilitation can be, from this point on, planned according to a quadrant-wise approach, which simplifies the therapy for both patient and clinician. Based on individual, patient-related criteria, the clinician and the technician can decide at which quadrant to start. Furthermore, having the plane of occlusion established with provisional restorations still allows minor modifications to be made. The vestibular cusps of the posterior provisional resin composites could be lengthened by adding new resin composite, or shortened by grinding.

One of the major advantages of the three-step technique consists of the fact that the opportunity to make modifications is maintained throughout the different treatment phases. Under such conditions it is not a surprise that the final esthetic outcome of this kind of full-mouth rehabilitation is consistently pleasing (Fig 19).

## Conclusions

Dental erosion is a frequently underestimated pathology, which affects an increasing number of younger individuals.<sup>34-35</sup>

Often the advanced tooth destruction is the result, not only of a difficult initial diagnosis (e.g. multifactorial etiology of tooth wear), but also of the lack of a timely intervention.

Traditionally, extensive dental therapies are previewed for these patients, and clinicians often prefer to wait until the tooth tissue loss is more conspicuous before proposing a conventional full-mouth rehabilitation. This hesitation finds its rationale in the aggressiveness of the conventional therapies.

Owing to the described novel and highly conservative approach, the University of Geneva, School of Dental Medicine has become one of the centers of reference for patients affected by advanced dental erosion.

In the past few years, a number of patients suffering from severely eroded dentitions have been treated according to this still experimental approach, which basically features minimal tooth preparation and maintenance of tooth vitality.

The new clinical approach (full-mouth adhesive rehabilitation) for the treatment of advanced generalized erosion, consists exclusively of posterior onlays and anterior BPRs, and is strategically planned in a way that allows rehabilitating patients quadrant-wise, instead of restoring both dental arches simultaneously

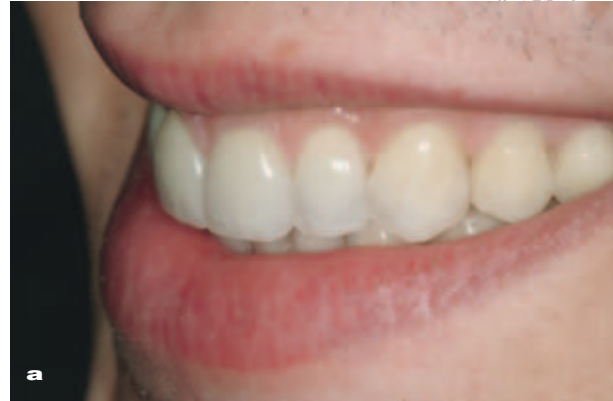
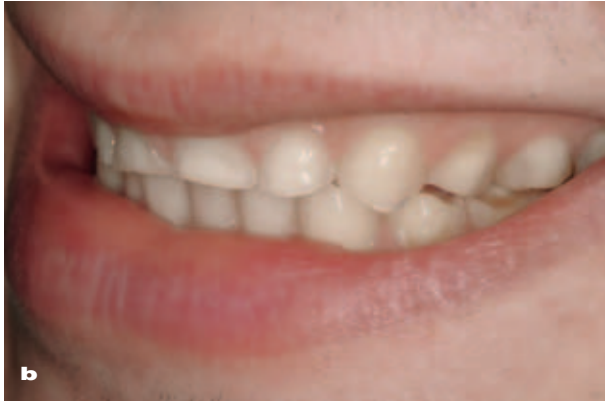Even though adhesive techniques simplify both the clinical and the laboratory procedures, restoring such compromised dentitions still remains a challenge due to the often advanced amount of tooth destruction.

To achieve maximum preservation of tooth structure and the most predictable esthetic and functional outcome, an innovative concept has been developed: the three-step technique.

Three laboratory steps are alternated with three clinical steps, allowing the clinician and the dental technician to constantly interact during the planning and execution of a full-mouth adhesive rehabilitation.



Not for Publication



**Fig 19a to d** 29-year old patient at completion of the adhesive rehabilitation. Thanks to the three-step technique, the occlusal plane and the incisal edge position are in harmony, as this was determined during the first step maxillary vestibular mock-up and continuously improved by minor modifications along the treatment.

In this article, the authors describe the third and last step of the three-step technique in detail. To reduce the risk of mechanical overload on the bonded restorations, patients who present parafunctional habits were not included in this clinical trial. How-

ever, the increased demand for treatment has led to eliminating this exclusion criterion. The next challenge will be to treat this population of patients and to document the long-term survival rate of their full-mouth adhesive rehabilitation.



## Acknowledgements

Treating the described complex cases is a team effort. Consequently, the authors would like to thank all the laboratory technicians and clinicians who have contributed to the final outcome of the different full-mouth rehabilitations, the laboratory technicians and ceramists: Alwin Schönenberger, Patrick Schnider, Serge

Erpen and Sylvain Carciofo for their meticulous execution of the laboratory work. Dr Giovanna Vaglio, Dr Federico Prando and Dr Tommaso Rocca for their enthusiastic collaboration and excellent clinical work, and finally Dr Olivier Marmy for his expertise during the temporomandibular consultations.

## References

1. Vailati F, Belser UC. Full-mouth adhesive rehabilitation of a severely eroded dentition: the three-step technique. Part I. *Eur J Esth Dent* 2008;3:30–44.
2. Vailati F, Belser UC. Full-mouth adhesive rehabilitation of a severely eroded dentition: the three-step technique. Part II. *Eur J Esth Dent* 2008;3:128–146.
3. Magne P, Belser UC. Bonded porcelain restorations in the anterior dentition. A biomimetic approach. Chicago: Quintessence Publishing Co 2002;266–267.
4. Panitvisai P, Messer HH. Cuspal deflection in molars in relation to endodontic and restorative procedures. *J Endod* 1995;21:57–61.
5. Reeh ES, Messer HH, Douglas WH. Reduction in tooth stiffness as a result of endodontic and restorative procedures. *J Endod* 1989;15:512–516.
6. Reeh ES, Douglas WH, Messer HH. Stiffness of endodontically treated teeth related to restoration technique. *J Dent Res* 1989;68:1540–1544.
7. Pjetursson BE, Sailer I, Zwahlen M, Hämmerle CH. A systematic review of the survival and complication rates of all-ceramic and metal-ceramic reconstructions after an observation period of at least 3 years. Part I: Single crowns. *Clin Oral Implants Res* 2007;18:73–85.
8. Sailer I, Pjetursson BE, Zwahlen M, Hämmerle CH. A systematic review of the survival and complication rates of all-ceramic and metal-ceramic reconstructions after an observation period of at least 3 years. Part II: Fixed dental prostheses. *Clin Oral Implants Res* 2007;18(Suppl 3):86–96.
9. Van Nieuwenhuysen JP, D'Hoore W, Carvalho J, Qvist V. Long-term evaluation of extensive restorations in permanent teeth. *J Dent* 2003;31:395–405.
10. Walton TR. An up to 15-year longitudinal study of 515 metal-ceramic FPDs: Part 2. Modes of failure and influence of various clinical characteristics. *Int J Prosthodont* 2003;16:177–182.
11. Walton TR. A 10-year longitudinal study of fixed prosthodontics: clinical characteristics and outcome of single-unit metal-ceramic crowns. *Int J Prosthodont* 1999;12:519–526.
12. Valderhaug J, Jokstad A, Ambjornsen E, Norheim PW. Assessment of the periapical and clinical status of crowned teeth over 25 years. *J Dent* 1997;25:97–105.
13. Walton JN, Gardner FM, Agar JR. A survey of crown and fixed partial denture failures: length of service and reasons for replacement. *J Prosthet Dent* 1986;56:416–421.
14. Coornaert J, Adriaens P, De Boever J. Long-term clinical study of porcelain-fused-to-gold restorations. *J Prosthet Dent* 1984;51:338–342.
15. Tan K, Pjetursson BE, Lang NP, Chan ES. A systematic review of the survival and complication rates of fixed partial dentures (FPDs) after an observation period of at least 5 years. *Clin Oral Implants Res* 2004;15:654–666.
16. Aquilino SA, Caplan DJ. Relationship between crown placement and the survival of endodontically treated teeth. *J Prosthet Dent* 2002;87:256–263.
17. Schwartz NL, Whitsett LD, Berry TG, Stewart JL. Unserviceable crowns and fixed partial dentures: life-span and causes for loss of serviceability. *J Am Dent Assoc* 1970;81:1395–1401.
18. Paul JE. Palatal inlays. *Br Dent J* 1994;177:239.
19. Bishop K, Briggs P, Kelleher M. Palatal inlays. *Br Dent J* 1994;177:365.
20. Magne P, Douglas WH. Interdental design of porcelain veneers in the presence of composite fillings: finite element analysis of composite shrinkage and thermal stresses. *Int J Prosthodont* 2000;13:117–124.



21. Magne P, Douglas WH. Cumulative effects of successive restorative procedures on anterior crown flexure: intact versus veneered incisors. *Quintessence Int* 2000;31:5–18.
22. Magne P, Douglas WH. Porcelain veneers: dentin bonding optimization and biomimetic recovery of the crown. *Int J Prosthodont* 1999;12:111–121.
23. Magne P, Douglas WH. Optimization of resilience and stress distribution in porcelain veneers for the treatment of crown-fractured incisors. *Int J Periodontics Restorative Dent* 1999;19:543–553.
24. Dietschi D, Spreafico R. Adhesive metal-free restorations. Berlin: Quintessence, 1997.
25. Magne P, Belser UC. Novel porcelain laminate preparation approach driven by a diagnostic mock-up. *J Esthet Restor Dent* 2004;16:7–16.
26. Gürel G. The science and art of porcelain laminate veneers. Chicago: Quintessence Publishing, 2003.
27. Magne P, Perroud R, Hodges JS, Belser UC. Clinical performance of novel-design porcelain veneers for the recovery of coronal volume and length. *Int J Periodontics Restorative Dent* 2000;20:440–457.
28. Magne P, Douglas WH. Porcelain veneers: dentin bonding optimization and biomimetic recovery of the crown. *Int J Prosthodont* 1999;12:111–121.
29. Magne P, Douglas WH. Additive contour of porcelain veneers: a key element in enamel preservation, adhesion, and esthetics for aging dentition. *J Adhes Dent* 1999;1:81–92.
30. Belser UC, Magne P, Magne M. Ceramic laminate veneers: continuous evolution of indications. *J Esthet Dent* 1997;9:197–207.
31. Garber D. Porcelain laminate veneers: ten years later. Part I: Tooth preparation. *J Esthet Dent* 1993;5:56–62.
32. Castelnuovo J, Tjan AH, Phillips K, Nicholls JI, Kois JC. Fracture load and mode of failure of ceramic veneers with different preparations. *J Prosthet Dent* 2000;83:171–180.
33. Magne P, Belser UC. Bonded porcelain restorations in the anterior dentition. A biomimetic approach. Chicago: Quintessence Publishing Co, 2002;30–37.
34. Deery C, Wagner ML, Longbottom C, Simon R, Nugent ZJ. The prevalence of dental erosion in a United States and a United Kingdom sample of adolescents. *Pediatr Dent* 2000;22:505–510.
35. Linnett V, Seow WK. Dental erosion in children: a literature review. *Pediatr Dent* 2001;23:37–43.