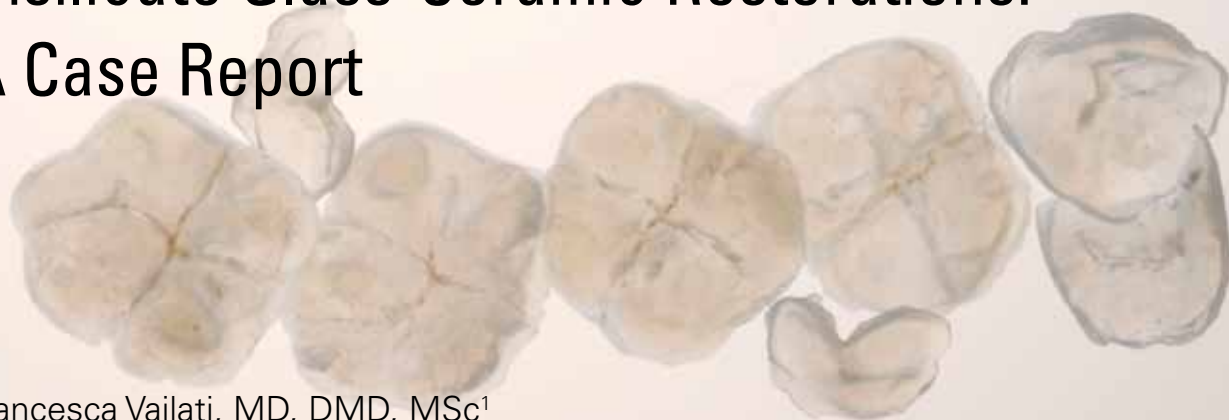


Minimally Invasive Treatment of Initial Dental Erosion Using Pressed Lithium Disilicate Glass-Ceramic Restorations: A Case Report



Francesca Vailati, MD, DMD, MSc¹

August Bruguera, MDT²

Urs Christoph Belser, DMD, Prof Dr Med Dent³

Dental erosion is spreading rapidly among younger generations of patients. Clinicians often underestimate the extent of this disease and postpone its treatment due to a lack of awareness or to uncertainty regarding the proper course of action. The discussion of when and how to treat young individuals affected by dental erosion has split the dental community into two groups: clinicians who treat eroded teeth excessively and clinicians who do not treat eroded teeth at all.

In this case report, a young adult patient affected by generalized dental erosion was treated even though his tooth degradation was only at an initial stage. The rationale behind this early intervention was that no or minimal tooth preparation would be required for treat-

ment. In fact, only additive adhesive procedures were implemented to replace the missing tooth structure and protect the remaining dentition from further damage.

[Au: Figure callouts have been provided throughout article; please confirm their correct placement.]

CASE REPORT

A 25-year-old male Caucasian patient presented to the School of Dental Medicine at the University of Geneva, Geneva, Switzerland. His chief complaint was the weakening and fracturing of his maxillary incisal edges. During a previous dental consultation, a parafunctional habit (bruxism) was suggested as the main cause of lost tooth structure; however, no occlusal guard had been prescribed. Clinical examination revealed that the patient also showed generalized initial dental erosion (Figs 1 to 6).

The patient presented accelerated loss of enamel, especially on the palatal aspect of the maxillary anterior teeth and occlusal surfaces of the premolars. In addition, the mandibular first molars presented concave occlusal surfaces with reduced areas of contact with the antagonistic teeth. Wear facets at the canines were also present, indicating moderate parafunctional habits. The remaining dentition was intact.

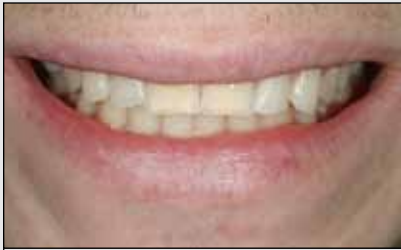¹Private Practice, Geneva, Switzerland; Senior Lecturer, Department of Fixed Prosthodontics and Occlusion, School of Dental Medicine, University of Geneva, Geneva, Switzerland.

²Director, Disseny Dental Laboratory and Dental Formation Center, Barcelona, Spain.

³Chairman, Department of Fixed Prosthodontics and Occlusion, School of Dental Medicine, University of Geneva, Geneva, Switzerland.

Correspondence to: Dr Francesca Vailati, School of Dental Medicine, rue Barthelemy-Menn 19, University of Geneva, 1205 Geneva, Switzerland. Email: Francesca.vailati@unige.ch

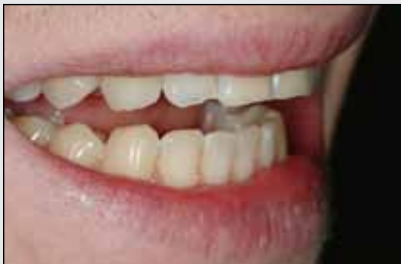CASE REPORT



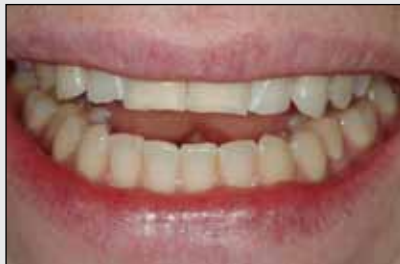1

Fig 1 Initial situation. Note the very conservative smile, showing the patient's insecurity regarding the eroded teeth. Also note the darker yellowish color of the maxillary central incisors.

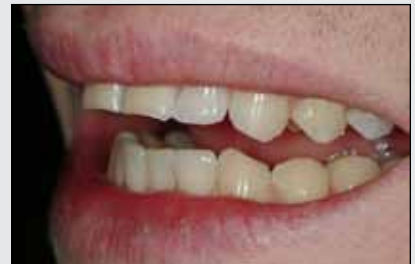Figs 2a to 2c The patient was asked to show an exaggerated smile with an open mouth, but the patient could not fully relax because he had learned to smile while covering as much of the teeth as possible. No gingiva was visible in the maxillary arch. Note the presence of a reverse smile due to the fracturing of the incisal edges of the maxillary anterior teeth.



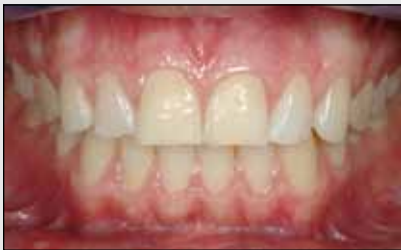2a



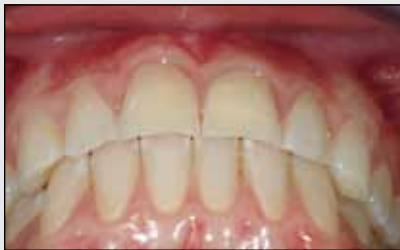2b



2c



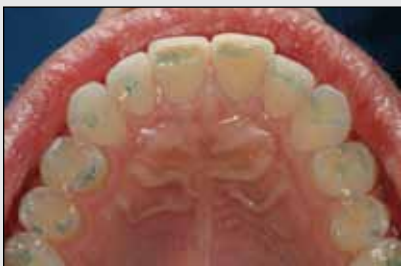3



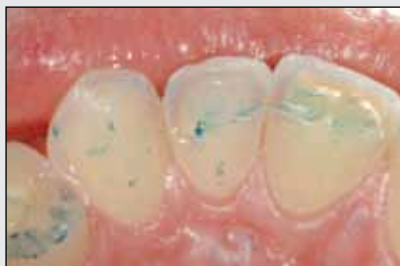4

Fig 3 Intraoral view. At this early stage of dental erosion, the teeth had not supraerupted, thus simplifying the restorative treatment plan.

Fig 4 The mandibular anterior teeth were intact, as is often the case with dental erosion.

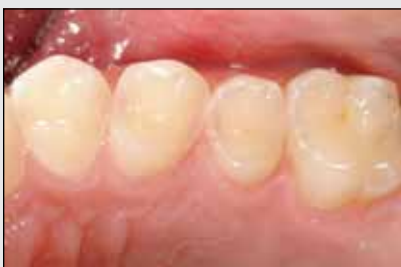

5a

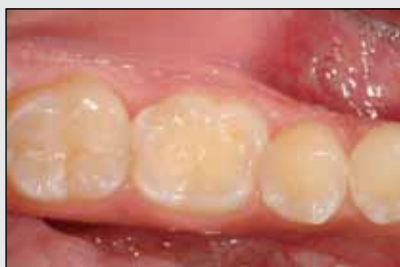

5b

Figs 5a and 5b Occlusal view and contact points. Since the patient did not have a deep bite (shallow vertical overlap), the risk of incisal edge fracture was high even at this early stage.



6a



6b

Figs 6a and 6b The maxillary premolars presented thinning of the enamel and small areas of exposed dentin. The mandibular first molars also presented thinning of the occlusal enamel and a concave occlusal surface.

The patient was questioned regarding the possible etiology of the dental erosion, and he denied any excessive consumption of acidic beverages or food. The clinician recommended further investigation of a possible intrinsic origin of the acid (eg, gastric reflux) through a visit to a gastroenterologist. However, the patient did not comply with this suggestion, and the etiology of the dental erosion remained unknown.

Anterior erosive classification (ACE)¹ was used to determine the extent of erosion. Following examination, the patient's erosion was classified as ACE class III because the palatal dentin was exposed at the level of the contact points with the antagonistic mandibular teeth and the incisal edges were starting to fracture (loss of less than 2.0 mm of the original tooth length). Since reduced vertical overlap (overbite) was a risk factor for accelerated damage of the incisal edges and the etiology of the problem was still unknown, the potential for a higher ACE classification was a concern (see Fig 5).

The benefits of early intervention were discussed, with special consideration paid to the young age of the patient. It was decided to restore the patient's affected teeth with no or minimal tooth preparation following exclusively adhesive principles.

ACE class III maxillary anterior teeth can only be restored using palatal veneers. To obtain the necessary interocclusal space to deliver the restorations without tooth preparation, an increase of the vertical dimension of occlusion (VDO) may be considered as long as no orthodontic measures are implemented. Since the posterior teeth also showed signs of dental erosion, it was decided to increase the VDO by restoring the posterior teeth as well.

In addition to the loss of tooth structure related to dental erosion, the patient presented esthetic problems at the maxillary central incisors (see Figs 1 to 4). Even though the facial aspect of these teeth was intact (except for their incisal edges), their coloring was darker compared to the rest of the dentition. Several unsuccessful attempts at external bleaching had been made in the past. The central incisors had changed color following prior trauma to the anterior teeth. At the radiographic examination, both pulp chambers were obliterated, and the vitality test was negative. However, neither radiographic signs of periapical lesions nor symptoms related to a loss of vitality were

evident. The percussion test was also negative. After consultation with an endodontist, it was decided to maintain the status quo without performing elective endodontic therapy until signs or symptoms of pulp necrosis arose. Consequently, two facial veneers were also planned to mask the discoloration.

Delivering two veneers, one palatal and one facial, to restore a single tooth is called the "sandwich approach," which has been proven to be the most conservative treatment for ACE class IV to VI anterior teeth. However, in this ACE class III patient, the sandwich approach was dictated more by the patient's esthetic demands than by loss of tooth structure.

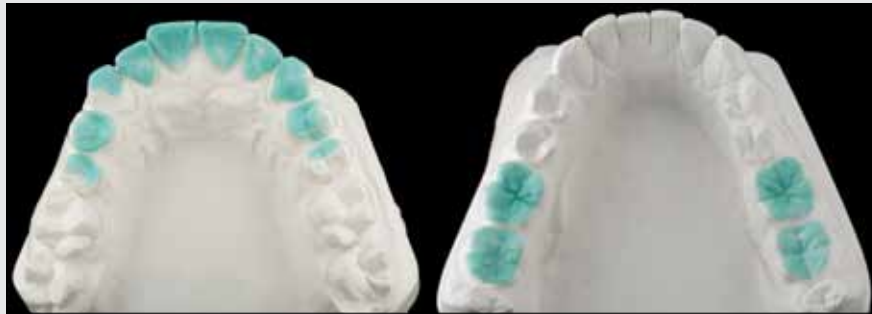Modified Three-Step Technique

Generally, patients at the University of Geneva affected by dental erosion are treated following the three-step technique.²⁻⁴ Due to the early detection of the erosion, this patient did not require full-mouth rehabilitation. Thus, a modified three-step technique was used.

The typical first step (maxillary vestibular mock-up) was not necessary because the occlusal plane did not require alteration and the shape of the maxillary anterior teeth needed only minor modification (lengthening of the incisal edges). Instead, treatment began directly with the increase of the VDO and creation of anterior open bite (step two). Due to the minimal increase of the VDO, no provisional restorations were necessary. Consequently, instead of the posterior provisional stage in the classic three-step technique, final restorations for the posterior teeth were fabricated.

During the first visit, two alginate impressions were taken, and casts were mounted on a semi-adjustable articulator using a facebow in maximum intercuspal position. The VDO was arbitrarily increased to obtain the space necessary to restore the occlusal surfaces of the posterior teeth and the palatal aspect of the maxillary anterior teeth.

The space gained in the posterior quadrants by the increased VDO was shared between the maxillary premolars and mandibular molars (Fig 7). Posterior support at the increased VDO was obtained only by insertion of the eight ceramic onlays for the premolars. The remaining posterior teeth were not involved in the restorative treatment.



7

Fig 7 As confirmed by the diagnostic wax-up, the interocclusal space obtained at the posterior quadrants was shared between the mandibular molars and maxillary premolars. Interdental spaces should be kept free of wax during wax-up procedures.

Once this stage of treatment was finalized, the patient was scheduled for another appointment. The final impression of the maxillary and mandibular arches was made using polyvinyl siloxane to fabricate the working casts.

Posterior Ceramic Onlays

An additive diagnostic wax-up was used as the starting point for fabrication of exceptionally thin and highly conservative posterior lithium disilicate ceramic onlays. Developing thin occlusal ceramic onlays while simultaneously providing adequate occlusal function is a complicated procedure. Conventional ceramic onlays require a minimum thickness of 1.5 to 2.0 mm, whereas thin occlusal ceramic onlays have a maximum thickness ranging from 0.5 to 0.6 mm. These highly conservative restorations can be produced with minimal or no tooth reduction and are highly indicated to restore eroded posterior teeth.

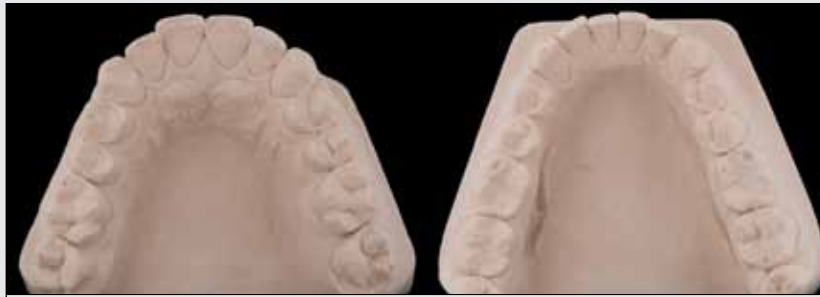Thin occlusal ceramic onlays are very fragile and may fracture during waxing or fabrication procedures. The first step is to make the investment casts. The working casts must be duplicated in the investment (Fig 8). The working casts are painted with die spacer (Color Spacer, Yeti Dental, Engen, Germany) and then duplicated using polyvinyl siloxane (Zhermack Elite, Zhermack, Badia Polesine, Italy) and phosphate-bonded investment material (IPS Press Vest Speed, Ivoclar Vivadent). When so-

called Geller or alveolar casts are used as the working casts, the teeth to be restored can be easily duplicated with the investment material (Fig 9).

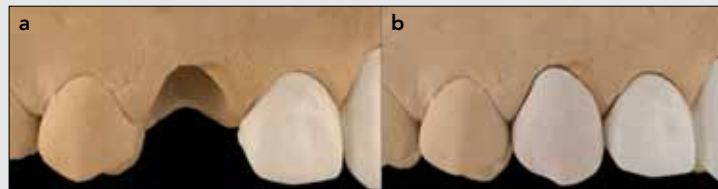
The wax-up of the occlusal onlays must be made directly on the investment replica following the morphology obtained in the wax-up. Waxing directly to the investment is a far more delicate procedure than waxing directly on the microstone. Since investment material is less rigid than stone, contact of the hot waxing instrument on the investment may damage its surface, resulting in permanent distortion (Figs 10 and 11).

Correct placement of the sprue is crucial during the fabrication of thin occlusal ceramic onlays (Fig 12). An inadequate placement and amount of wax for the sprue may result in loss of the ceramic onlay's peripheral contour. A solution for this drawback is to wax the sprue directly over the investment. This procedure allows better contour and marginal fit without removing the wax before investment into the cylinder. Once the restorations are waxed with the correctly located sprue, the investment material surrounding the restorations is carefully trimmed, leading to individual waxed investment dies. Trimming the investment around the waxed tooth facilitates positioning into the investment ring. However, before positioning the whole set into the investment ring, the investment dies should be soaked in alcohol to prevent them from absorbing moisture from the investment coating too quickly.

The thin occlusal onlays were made with a highly opalescent shade ingot (Impulse 01, IPS e.max Press,



8



9

Fig 8 The preoperative casts were duplicated in investment material to facilitate waxing of the thin occlusal onlays.

Figs 9a and 9b With Geller or alveolar casts, only the teeth to be restored can be duplicated in investment material.

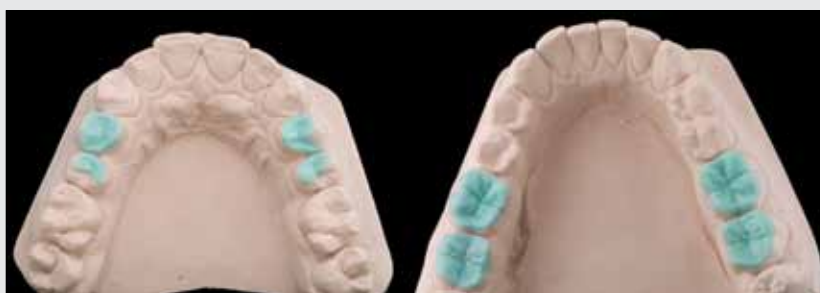Fig 10 To avoid permanent distortion, the hot waxing instrument must not touch the investment.



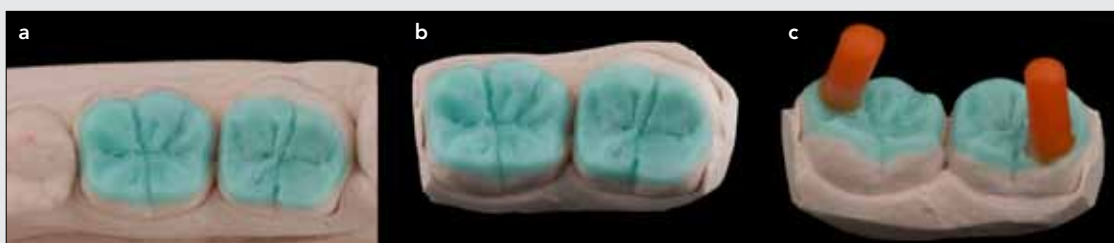10

Fig 11 The study wax-up must be replicated in the investment casts.

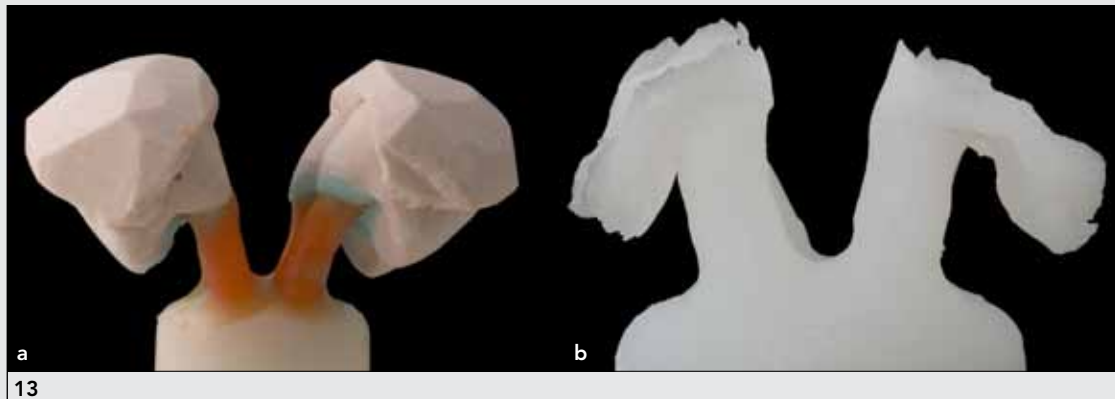
Figs 12a to 12c (a) Close-up view of the waxed restoration; (b) the investment surrounding the wax-up was carefully trimmed; (c) correct placement of the sprues for thin occlusal onlays.



11



12



13

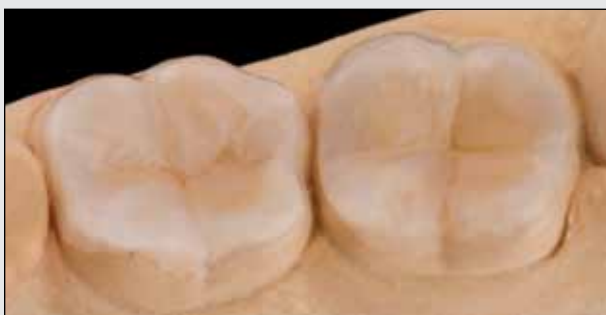

14

Figs 13a and 13b (a) Thanks to this new investment technique, thin occlusal onlays can be pressed on top of retentive areas; (b) pressed thin occlusal onlays.

Fig 14 Highly opalescent ingots.

Figs 15a and 15b (a) Occlusal view of the thin occlusal veneers after adjustment to the master cast; (b) 0.6-mm-thin occlusal onlays.



15a



15b

Ivoclar Vivadent) to match the natural teeth (Figs 13 and 14). According to the manufacturer, opal ingots can be used as enamel replacements because of their optical properties and adequate strength. To provide suitable optical properties, the maximum thickness of the opalescent ingot must not exceed 0.5 to 0.6 mm (Fig 15). Thicker restorations often result in an undesirable increase in value. The final step is to glaze the restorations as recommended by the manufacturer.

The patient was informed that the third appointment would be a long one since the eight ceramic onlays had to be inserted in the same visit. No anesthesia was required, and the field was isolated with rubber dam. Figures 16 to 23 demonstrate the placement procedures. Enamel was etched (37% phosphoric acid) for 30 seconds, and the adhesive resin (Optibond FL, Kerr,

Orange, California, USA) was applied on the teeth and left unpolymerized.

The pressed lithium disilicate glass-ceramic onlays were etched with hydrofluoric acid for 20 seconds and cleaned in alcohol in an ultrasonic bath. Three coats of silane were applied (Monobond Plus, Ivoclar Vivadent) to the intaglio surfaces of the restorations, and a final layer of the adhesive resin was added without curing.

A microhybrid composite resin (Enamel plus, Micrimerium, Avegno, Italy) was heated and applied to the restorations before they were placed on the teeth and light polymerized. The challenge was to bond the ceramic onlays while maintaining the original interproximal contacts. In addition, the extremely thin onlays required additional attention to avoid fracture during the bonding procedure.

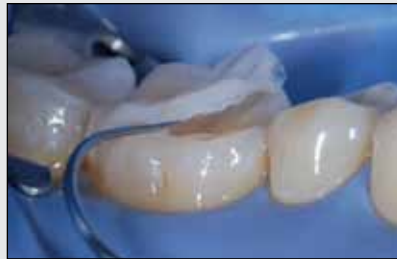Figs 16a and 16b Extremely thin onlays were delivered to restore the mandibular molars.

Figs 17a and 17b Irregular margins were smoothed with a diamond bur.

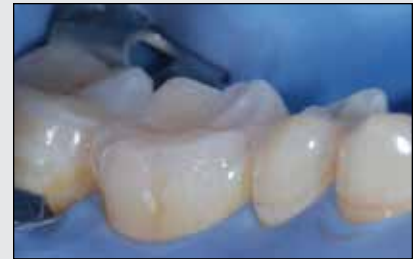Figs 18a and 18b Onlay try-in at the maxillary premolars. The two onlays were bonded at the same time. Metal strips were used to keep the teeth apart.

Fig 19 The exposed dentin was roughened with a coarse diamond bur to eliminate the most superficial layer.

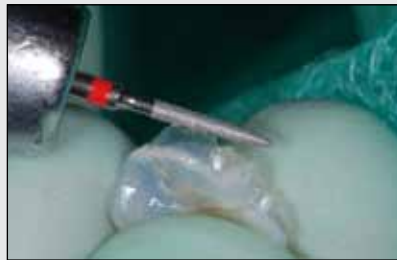Fig 20 Enamel was etched with phosphoric acid for 30 seconds. Dentin was etched for 15 seconds.



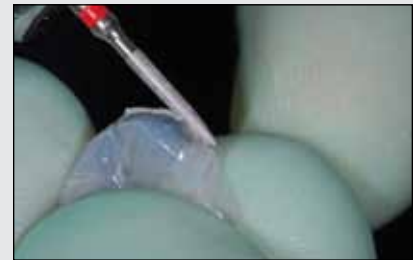16a



16b

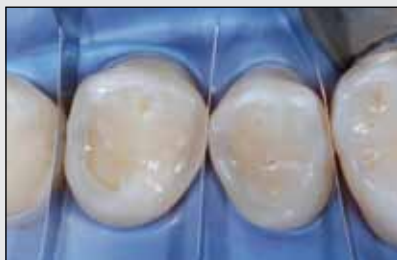
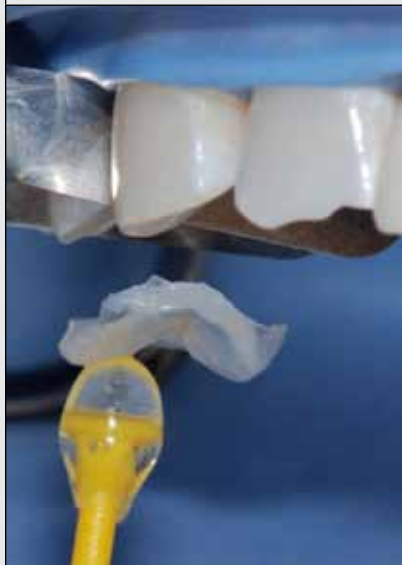
17a

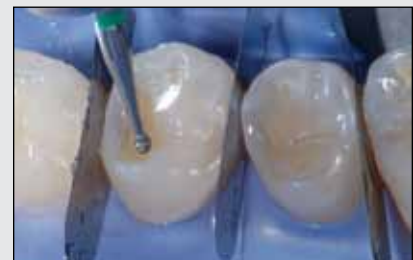

17b

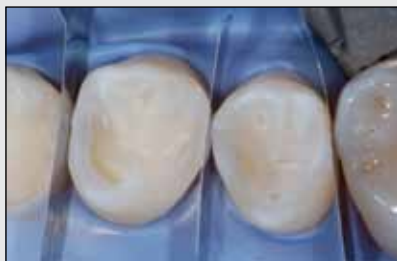18a



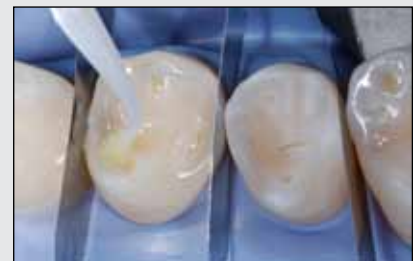18b



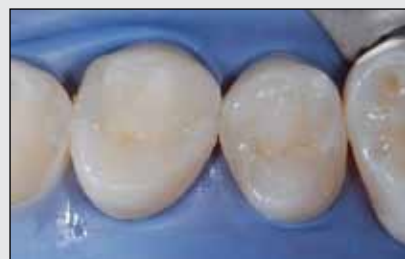19



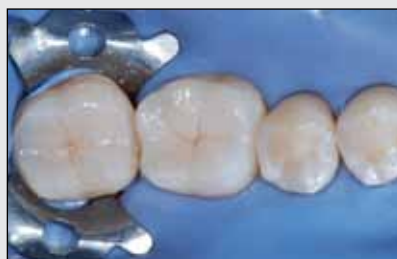20



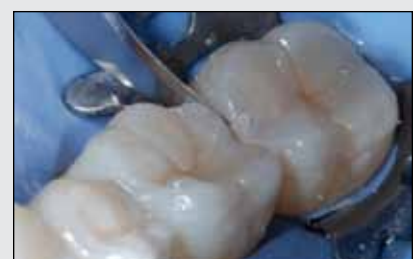21



22a



22b

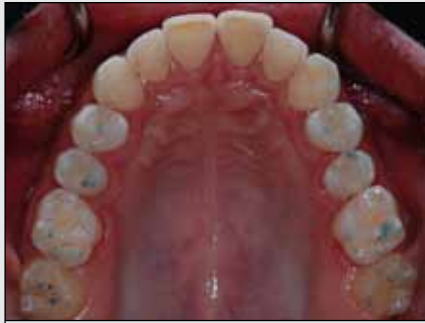

23

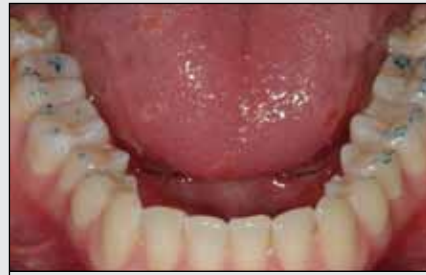Fig 21 An ethanol- and water-based three-step etch-and-rinse was used (Optibond FL). The bond was not cured. Immediate dentin sealing was not carried out before the final impression due to the minimal dentin exposure and risk of creating interference with the occlusion.

Figs 22a and 22b Some excess cement remained due to the closed interproximal contact and the presence of the metal strips.

Fig 23 A scalpel was used to remove the excess composite resin.

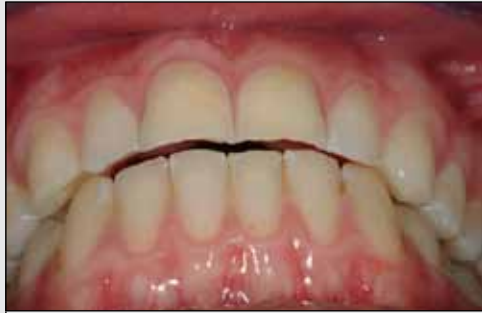

24a



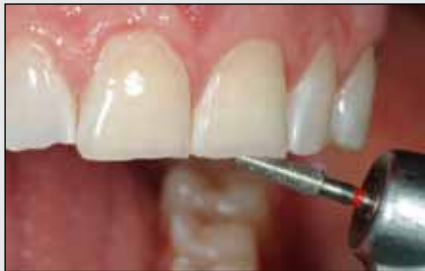24b

Figs 24a and 24b After delivery of final posterior restorations, the patient presented stable occlusion in the posterior quadrants.



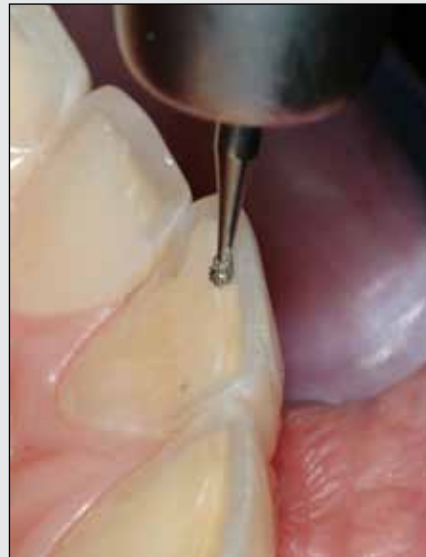25

Fig 25 The increased VDO with the contact points only on the posterior teeth generated an anterior open bite. This space was sufficient for the palatal veneers.



26a

Figs 26a and 26b Preparation for the six palatal veneers. The unsupported enamel prisms were smoothed at the incisal edge, and the exposed dentin was sealed before the final impression.



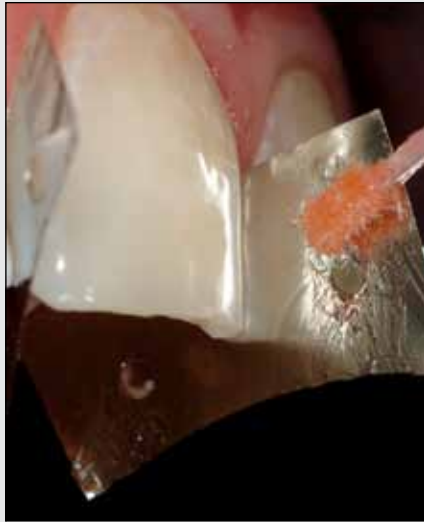26b

Anterior Veneers

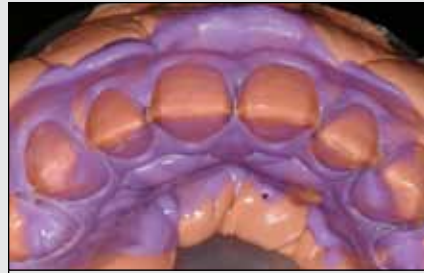The patient's new occlusion was controlled after 1 week to intercept occlusal interferences (Figs 24 and 25). The patient was comfortable, and no signs of temporomandibular joint disorders were detected.

In the following appointment, the palatal aspect of the maxillary anterior teeth was prepared for the palatal veneers (Fig 26). All exposed dentin was im-

mediately sealed without anesthesia. The palatal dentin was cleaned with non-fluoridated pumice, and the most superficial layer was removed with diamond burs. The exposed sclerotic dentin was etched with 37% phosphoric acid for 15 seconds and immediately sealed with three-step etch-and-rinse ethanol- and water-based adhesive (Optibond FL) and flowable composite resin (Tetric Flow T, Ivoclar Vivadent) just before the final impression was taken.⁵⁻⁹



27a



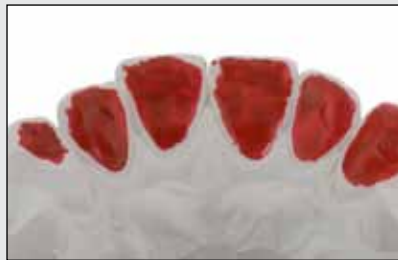27b

Figs 27a and 27b The final impression was taken with the interproximal contacts closed. To facilitate trimming of the dies, metallic matrix bands were placed in between the teeth. Access holes and the application of adhesive were used to ensure that the strips were removed with the tray during impression taking [Au: Sentence correct as edited?].

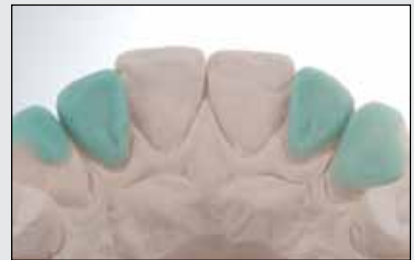Fig 28 Die spacer was applied to the master cast before duplication.

Fig 29 In the investment cast, the palatal veneers were waxed similarly to the occlusal onlays.

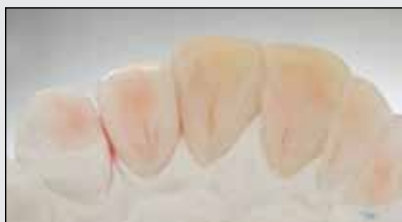Figs 30a to 30c Palatal view of the finished veneers. The maxillary lateral incisors and canines were made with highly opalescent pressed ceramic (Impulse 1, IPS e.max Press), whereas the maxillary central incisors were made with composite resin (Adoro).



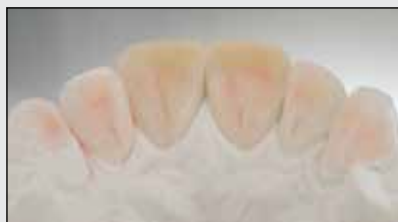28



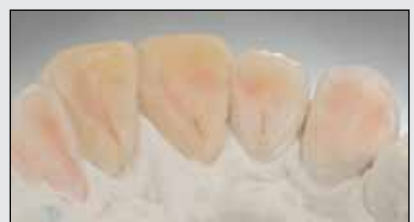29



30a



30b



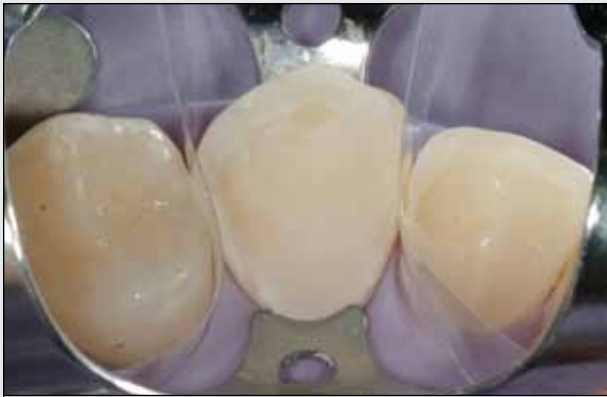30c

Finally, the irregular margins of the incisal edges were smoothed. No additional tooth preparation was necessary. The interproximal contacts between the maxillary anterior teeth were left closed, and the final impression was taken using metal strips in between the teeth, as for the posterior teeth (Fig 27). No provisional restorations were delivered.

It was decided to fabricate the palatal veneers in pressed lithium disilicate glass-ceramic (IPS e. max Press) for the maxillary lateral incisors and canines and in composite resin (Adoro, Ivoclar Vivadent) for the

maxillary central incisors. The presence of composite resin on the palatal aspect would facilitate not only the bonding procedure with the future ceramic facial veneers (sandwich approach), but also the eventual creation of an access hole for future root canal treatment.

The same laboratory technique described for the thin occlusal ceramic onlays was adopted for the palatal veneers, with the exception of those for the maxillary central incisors (Figs 28 and 29). For the central incisors, a laboratory microfilled composite resin was used (Fig 30).

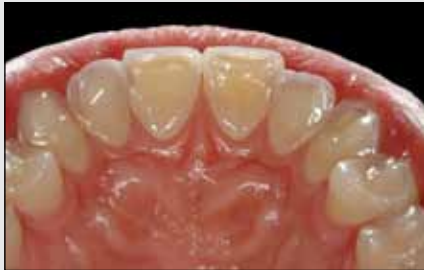

31

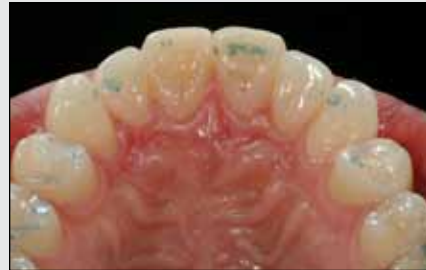Fig 31 Each palatal veneer was individually bonded using rubber dam. Note the closed interproximal contacts.

Figs 32a and 32b (a) Before and (b) after reestablishment of the anterior contacts and guidance using palatal veneers.

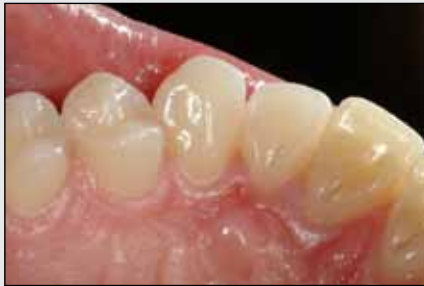Fig 32c Occlusal view of the palatal and occlusal veneers on the premolars.



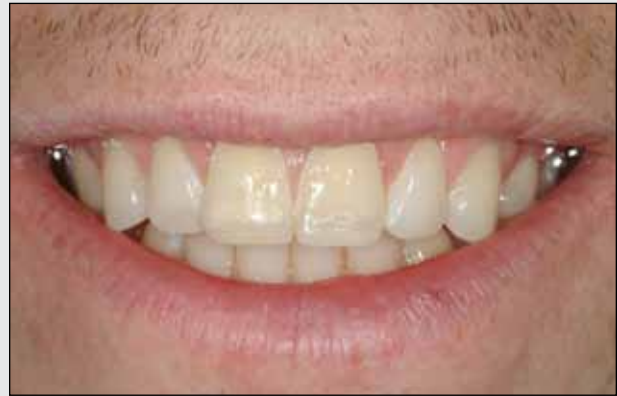32a



32b



32c



33

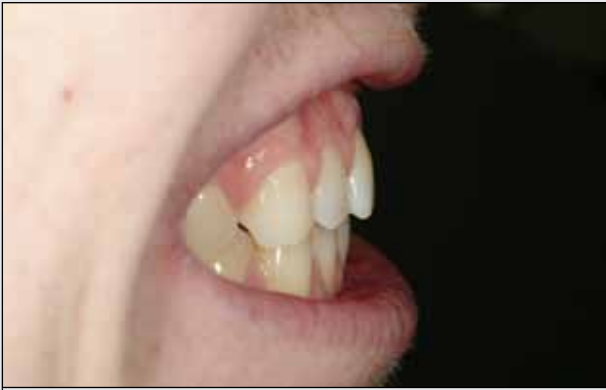Fig 33 Frontal view after completion of the modified three-step technique. The new edges of the lateral incisors were well blended, whereas the central incisors showed a highly translucent band at the interface with the palatal veneers. Due to the color discrepancy, it was proposed to remove the length added by the composite resin restorations. However, the patient preferred to keep the teeth longer until the facial veneer preparation.

[Au: only four palatal ceramic veneers, correct? Other two are composite resin?]

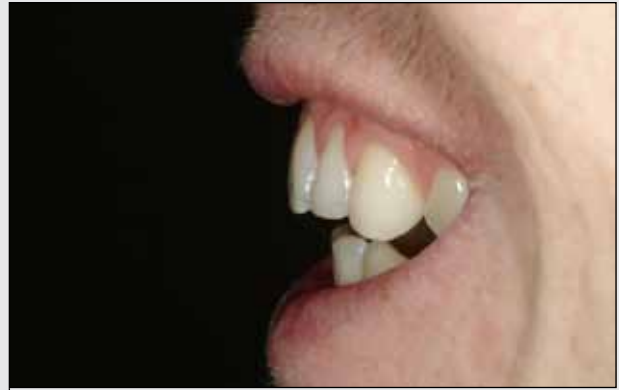After 2 weeks, the six palatal ceramic veneers were bonded, one at a time, under rubber dam without anesthesia (Fig 31). A three-hour appointment was necessary. The sealed palatal dentin was tribochemically coated (Cojet, 3M ESPE, St Paul, Minnesota, USA), the surrounding enamel was etched with 37% phosphoric acid for 30 seconds, and the adhesive (Optibond FL) was applied to the enamel and dentin and left uncured.

The intaglio surfaces of the palatal composite resin veneers were also tribochemically coated. The four pressed ceramic palatal veneers were etched with hydrofluoric acid for 20 seconds.

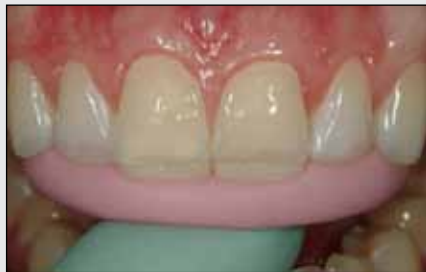All veneers were cleaned in alcohol and placed in an ultrasonic bath, followed by the application of three coats of silane (Monobond Plus). A coat of the adhesive resin was placed and left unpolymerized. Compos-



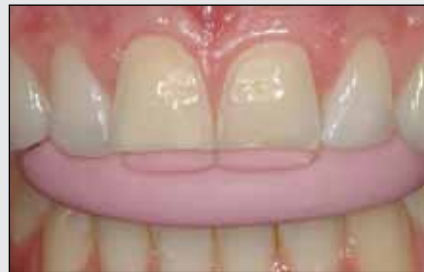34a



34b



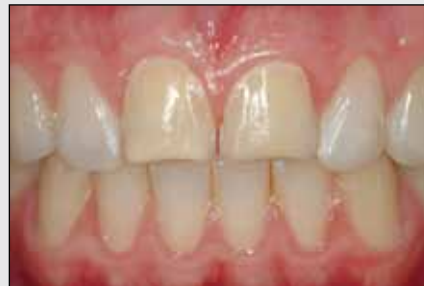35a



35b

Figs 34a and 34b Profile views (a) before and (b) after restoration of the incisal edges using palatal veneers.

Figs 35a to 35c Facial veneer preparation. The original teeth were very wide mesiodistally. Minimal preparation was necessary at this level. The original tooth length was preserved.



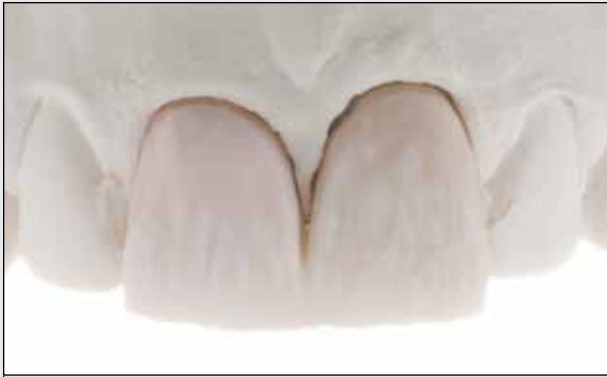35c

ite resin (Enamel plus) was heated and applied to the restorations before they were placed on the teeth and then light polymerized for 90 seconds for each surface. Following the completion of the modified three-step technique, the patient presented stable occlusion at an increased VDO (Figs 32 and 33). The incisal edges were also strengthened by the presence of the palatal veneers (Fig 34).

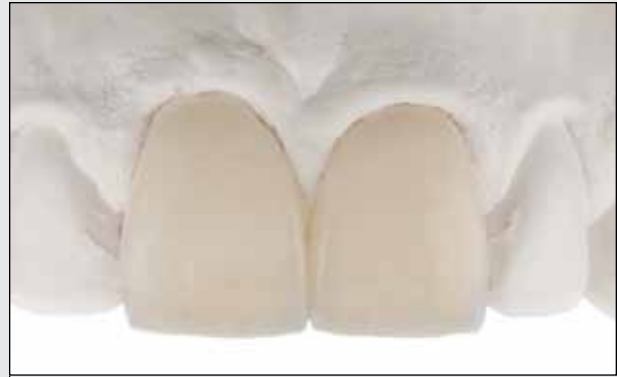To complete the treatment, the next step was the restoration of the facial aspect of the maxillary central incisors. Unfortunately, the initial position of these teeth was very labial. To keep the tooth preparation to a minimum, the prospect of a slightly bulkier facial surface was discussed with the patient (additive ap-

proach). Thanks to the preview provided by the mock-up on the central incisors, the patient agreed to the slightly thicker teeth. The option to restore the facial aspect of the lateral incisors was not considered due to the principle of minimal invasiveness. Unfortunately, minimal tooth preparation of the central incisors was inevitable due to their dark yellowish color. Facial veneers with a thickness of 1.0 mm were necessary to mask the underlying color. Because the teeth did not respond to the vitality test, no local anesthesia was necessary for the preparation (Fig 35).

After the final impression, provisional restorations were fabricated directly in the mouth using a provisional composite resin material (Telio, Ivoclar Vivadent), and



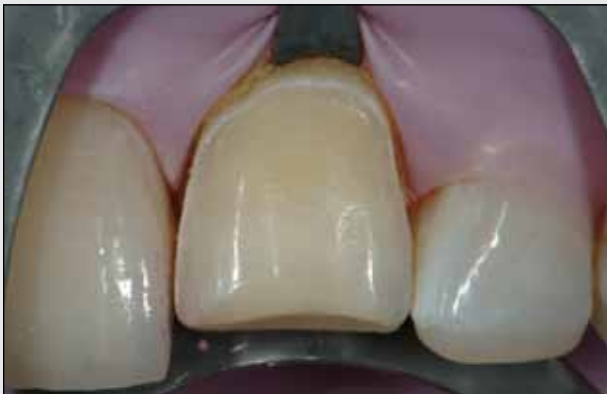36a



36b



36c



37

Figs 36a to 36c (a) Feldspathic porcelain veneer build-up; (b and c) extremely thin and highly translucent porcelain veneers.

Fig 37 Rubber dam isolation for veneer placement. A clamp with a retraction cord was used to ensure exposure of the gingival margins. The veneer preparation was confined to enamel. Remaining composite resin is still visible at the incisal surface. No dentin was exposed.

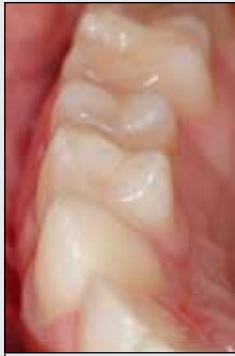retention was achieved by the contraction of the product and the presence of minimal interproximal excess.

The labial veneers were fabricated using the refractory die technique and feldspathic porcelain (Fig 36). Ceramic layering was performed to better match the color and optical details of the adjacent anterior teeth. These highly translucent facial veneers blend easily with the underlying preparation.

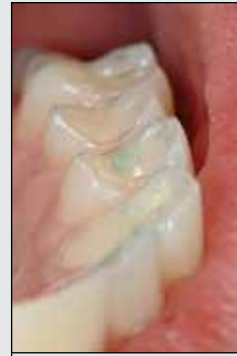Bonding of the feldspathic ceramic veneers was carried out after 2 weeks, following the protocol developed by Magne et al (Fig 37).¹⁰⁻¹⁴ Final external bleaching provided a pleasing esthetic outcome. The

patient was very satisfied with the overall treatment (Figs 38 to 40). In terms of biologic success, no tooth preparation was performed for this almost full-mouth rehabilitation except for the facial surfaces of the maxillary central incisors.

The incisal edges of the maxillary anterior teeth were reinforced by the presence of the restorative materials, the exposed dentin was covered, and the thinner enamel was also reinforced. An occlusal guard was delivered to the patient to control his light parafunctional habit, and a visit to a gastroenterologist was again recommended.



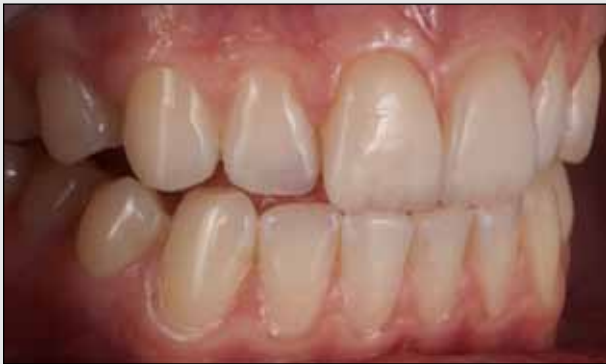38a



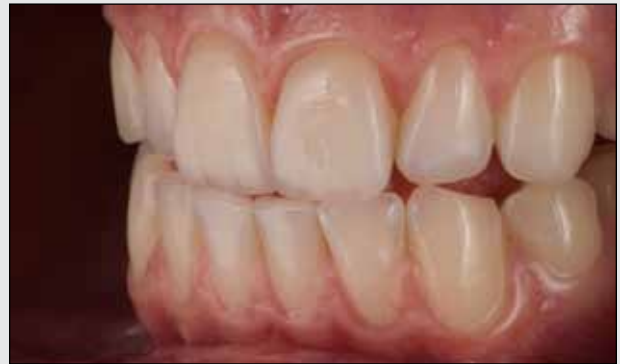38b

Figs 38a and 38b The onlays restored the convex profile of the occlusal surfaces.

Figs 39 and 40 Final result.



39a



39b



40

CONCLUSION

This article presented a case report of a patient affected by initial dental erosion. Early intervention was performed due to the exposed dentin and risk of fracture of the anterior teeth. Only time will tell if this type of early and minimally invasive approach is the best solution for patients affected by dental erosion.

REFERENCES

- Vailati F, Belser UC. Classification and treatment of the anterior maxillary dentition affected by dental erosion: The ACE classification. *Int J Periodontics Restorative Dent* 2010; 30:559–571.
- Vailati F, Belser UC. Full-mouth adhesive rehabilitation of a severely eroded dentition: The three-step technique. Part 3. *Eur J Esthet Dent* 2008;3:236–257.
- Vailati F, Belser UC. Full-mouth adhesive rehabilitation of a severely eroded dentition: The three-step technique. Part 2. *Eur J Esthet Dent* 2008;3:128–146.
- Vailati F, Belser UC. Full-mouth adhesive rehabilitation of a severely eroded dentition: The three-step technique. Part 1. *Eur J Esthet Dent* 2008;3:30–44.
- Bertschinger C, Paul SJ, Lüthy H, Schärer P. Dual application of dentin bonding agents: Effect on bond strength. *Am J Dent* 1996; 9:115–119.
- Paul SJ, Schärer P. The “Dual Bonding Technique”—A modified method to improve adhesive luting procedures. *Int J Periodontics Restorative Dent* 1997;17:537–545.
- Magne P, So WS, Cascione D. Immediate dentin sealing supports delayed restoration placement. *J Prosthet Dent* 2007;98: 166–174.
- Magne P, Kim TH, Cascione D, Donovan TE. Immediate dentin sealing improves bond strength of indirect restorations. *J Prosthet Dent* 2005;94:511–519.
- Magne P. Immediate dentin sealing: A fundamental procedure for indirect bonded restorations. *J Esthet Restor Dent* 2005;17: 144–154.
- Belser UC, Magne P, Magne M. Ceramic laminate veneers: Continuous evolution of indications. *J Esthet Dent* 1997;9:197–207.
- Magne P, Belser UC. Novel porcelain laminate preparation approach driven by a diagnostic mock-up. *J Esthet Restor Dent* 2004;6:7–16.
- Magne P, Perroud R, Hodges JS, Belser UC. Clinical performance of novel-design porcelain veneers for the recovery of coronal volume and length. *Int J Periodontics Restorative Dent* 2000;20:440–457.
- Magne P, Douglas WH. Porcelain veneers: Dentin bonding optimization and biomimetic recovery of the crown. *Int J Prosthodont* 1999;12:111–121.
- Magne P, Douglas WH. Additive contour of porcelain veneers: A key element in enamel preservation, adhesion, and esthetics for aging dentition. *J Adhes Dent* 1999;1:81–92.