



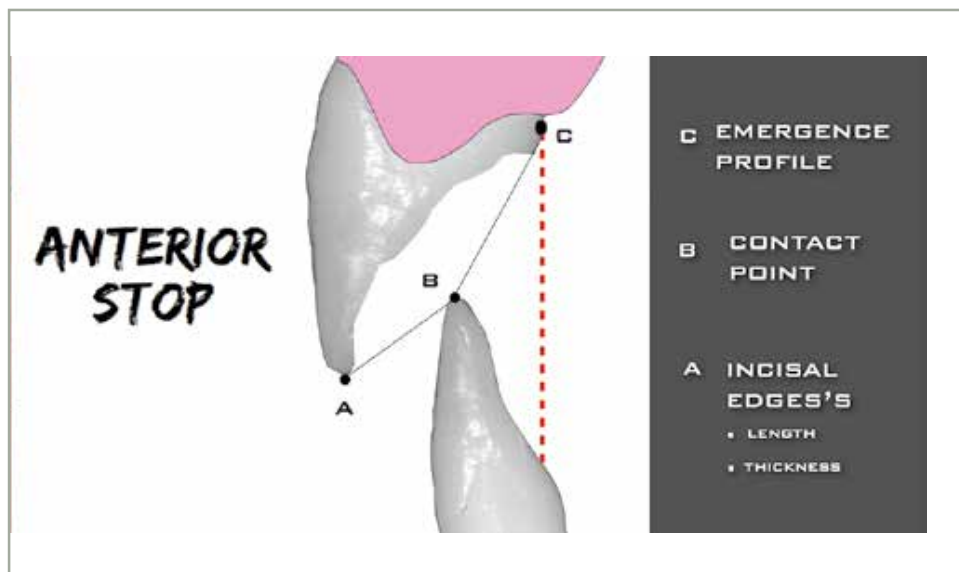
# Treatment planning of adhesive additive rehabilitations: the progressive wax-up of the three-step technique

**Francesca Vailati**, MD, DMD, MSc

Private practice, Geneva Dental Team, Geneva, Switzerland  
Senior Lecturer, Department of Fixed Prosthodontics and Biomaterials,  
University Clinic for Dental Medicine, Geneva, Switzerland

**Sylvain Carciofo**, MDT

Chief Dental Technologist,  
University Clinic for Dental Medicine, Geneva, Switzerland



Correspondence to: Dr Francesca Vailati

Geneva Dental Team, Rue St-Léger 8, 1205 Geneva; Tel.: 022 310 74 56; Fax: 022 312 32 21; E-mail: francesca.vailati@unige.ch

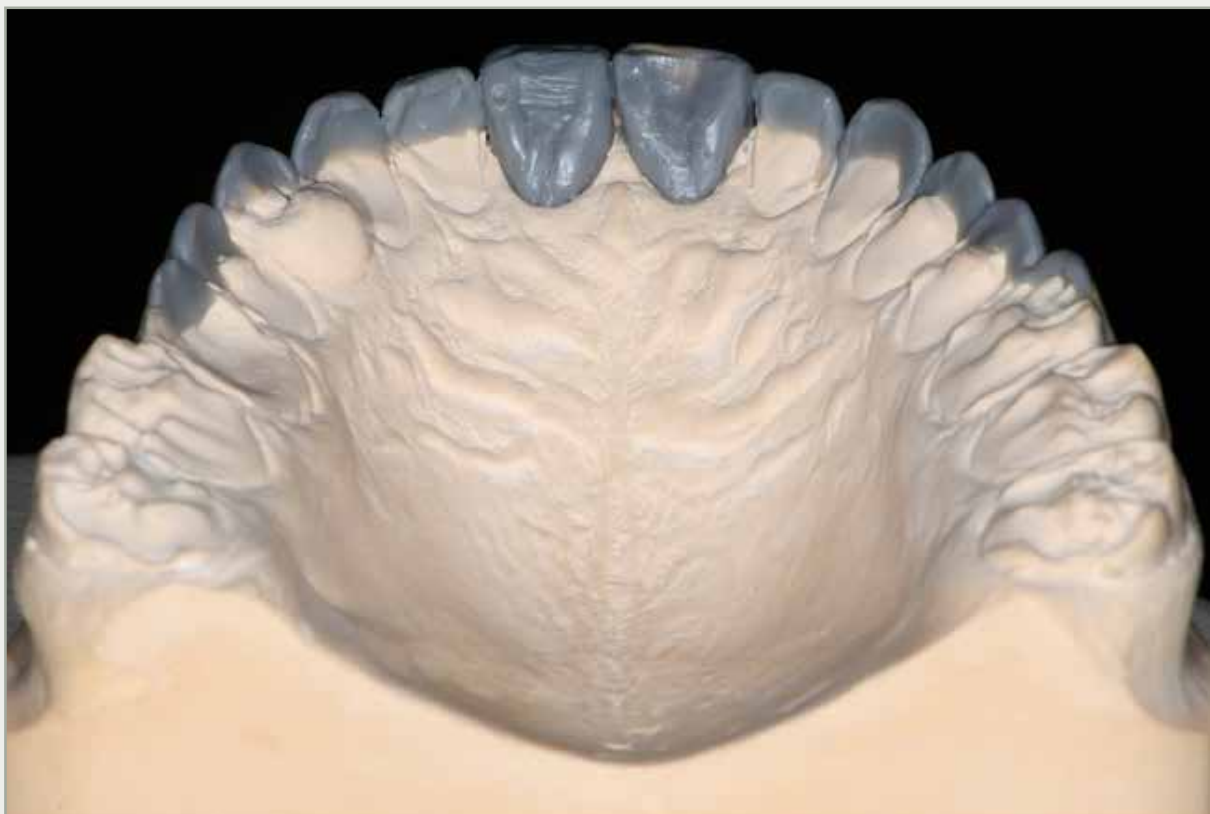

## Abstract

A full-mouth rehabilitation should be correctly planned from the start by using a diagnostic wax-up to reduce the potential for remakes, increased chair time, and laboratory costs. However, determining the clinical validity of an extensive wax-up can be complicated for clinicians who lack the experience of full-mouth rehabilitations. The three-step technique is a simplified approach that has been developed to facilitate the clinician's task. By following this technique,

the diagnostic wax-up is progressively developed to the final outcome through the interaction between patient, clinician, and laboratory technician. This article provides guidelines aimed at helping clinicians and laboratory technicians to become more proactive in the treatment planning of full-mouth rehabilitations, by starting from the three major parameters of incisal edge position, occlusal plane position, and the vertical dimension of occlusion.

*(Int J Esthet Dent 2016;11:XXX-XXX)*





### Introduction

When a dentition is severely compromised, a full-mouth wax-up is generally considered mandatory to reassure the clinician that the case is comprehensively analyzed. Unfortunately, at the end of the therapy, clinicians often realize that the initial full-mouth wax-up did not correspond to the final outcome of the rehabilitation, to the point that questions arise as to its real clinical value. The reason for this may be that clinicians allow laboratory technicians to make independent decisions about several clinical parameters, which increases the chance for error.

An approach has been developed to simplify the full-mouth rehabilitation treatment plan – the three-step technique – which considers three fundamental parameters: the vertical dimension of occlusion (VDO), the incisal edge position, and the occlusal plane position.<sup>1-7</sup> Since the three-step technique advocates the principles of minimally invasive to non-invasive dentistry, an increase of the VDO is strongly advocated for every full-mouth rehabilitation to avoid the need for tooth preparation (additive dentistry). In addition, the incisal edge position of the final restorations is essential to satisfy the patient's esthetic needs. Finally, the occlusal plane position not only has an important esthetic value, but also defines how to share the interocclusal space obtained with the increase of the VDO at the level of the posterior teeth.

In the authors' opinion, a full-mouth wax-up where these three parameters are considered at the same time is risky. Since the parameters are closely related

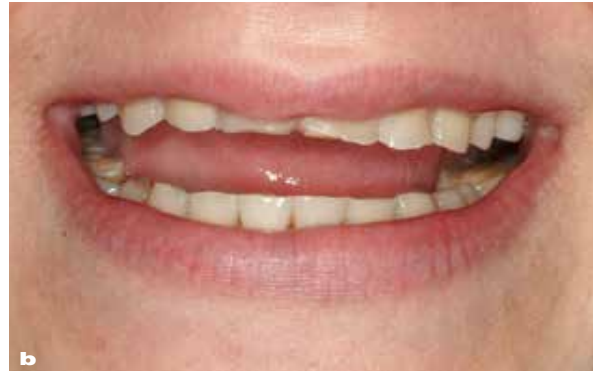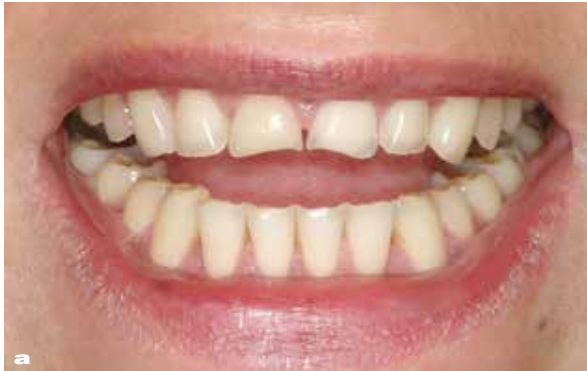to each other, a change to one necessarily entails a modification to another. In this way, the wax-up may become useless. For example, if a mock-up is made out of the full-mouth wax-up, and the patient asks for the incisal edges to be shortened, the occlusal plane must also be modified to avoid an unesthetic reverse smile; and if this latter aspect is modified, the occlusal wax-up should be remade. The full-mouth wax-up has then become useless.

The three-step technique prefers, instead, a partial wax-up that will progress after being evaluated and validated by the clinician at several stages. In *laboratory step I*, the laboratory technician will wax up only the vestibular aspect of the maxillary teeth, and the clinician will validate only the incisal edges and the occlusal plane. In *laboratory step II*, wax will be placed on the occlusal surfaces of specific posterior teeth, and the clinician will approve the occlusal plane position and the increase of the VDO. Finally, in *laboratory step III*, the wax-up will recreate the palatal aspect of the maxillary anterior teeth, and the clinician will give an opinion on the incisal length and the increase of the VDO.

### Step I

#### The esthetic

Since satisfying the patient's esthetic needs is a major objective, clinicians should take the time to really understand what will be considered esthetic for each patient. Trying to impose the clinician's taste on the final restorations may be highly risky. The risk of not ac-



**Fig 1a and b** In case of the destruction of the incisal edges, it is recommended to involve patients *as soon as possible* in the important decision about the esthetic of their future smile, since not everyone is ready to accept longer and wider restorations.

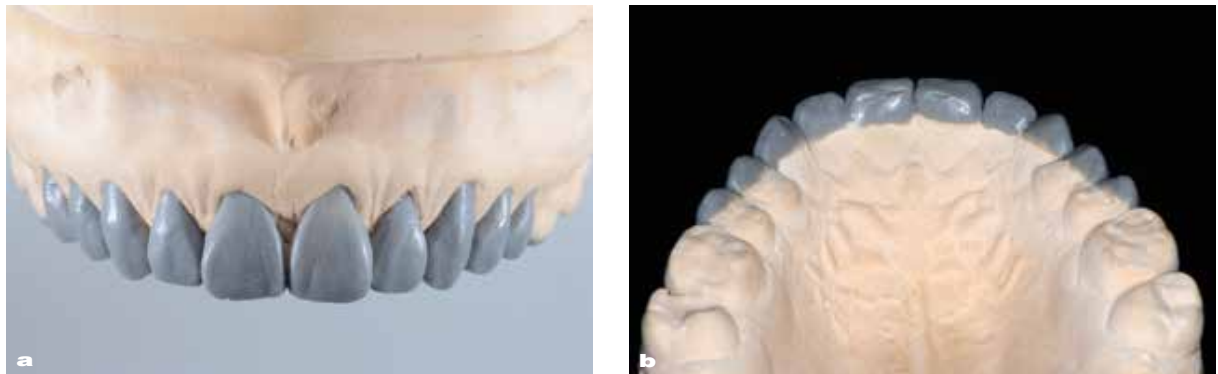
cepting the shape of the maxillary anterior teeth is higher in patients affected by dental erosion, especially in severe cases. Although these patients claim to be dissatisfied with their smile, they are often more accustomed to the look of their irregular, small, and yellowish teeth than they imagine, and drastic change can be difficult for them to accept.

To avoid lengthy discussions and costly remakes, it is advisable to identify the shape and color of the final restorations as soon as possible. Larger, longer, whiter teeth may be shocking for the patient, and the initial negative reaction does not always change to an acceptance of the new proposed smile design. A tridimensional mock-up, which also involves the maxillary posterior teeth, may be more useful to communicate with these patients (Fig 1).<sup>8</sup> Consequently, in the three-step technique, while a full-mouth wax-up is not considered necessary, a more extended mock-up is a fundamental step for understanding the patient's esthetic wishes. This mock-up

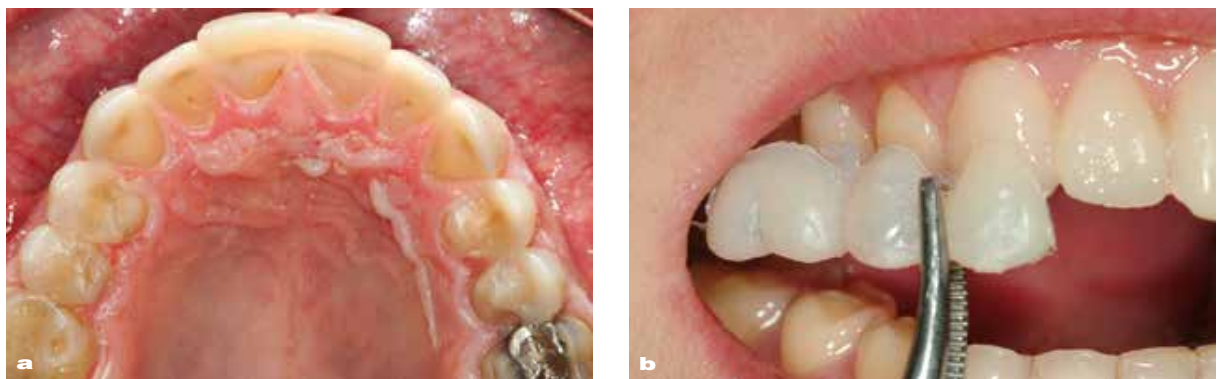
should be done as soon as possible, before investing in an extensive wax-up of the posterior teeth.

Following the three-step technique, the two casts (out of alginate impressions) are articulated in maximum interocclusal position (MIP) on a semi-adjustable articulator using a facebow. The first partial wax-up will cover only the vestibular surface of the maxillary teeth, sufficient to recreate the incisal edges and the occlusal plane at the level of the maxillary teeth (maxillary vestibular wax-up). Inspired by the photographs of the patient's smile, the laboratory technician will focus exclusively on the esthetic appearance, with maximum freedom of creativity (Figs 2 and 3).

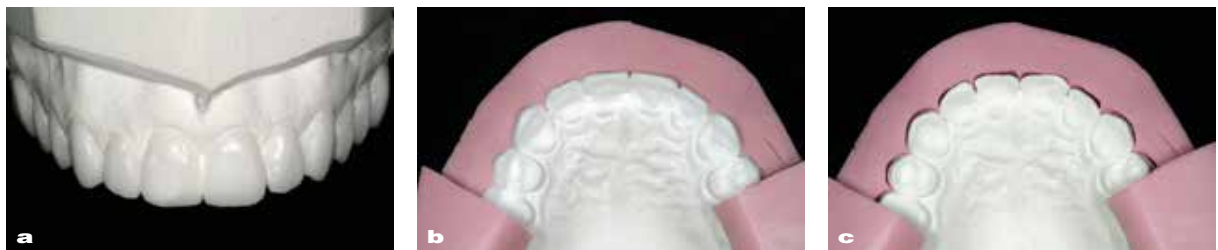Since the rehabilitation is driven by minimally invasive to non-invasive dentistry, laboratory technicians should remember to always thicken the teeth during this wax-up so that the vestibular aspect of the teeth can be left intact during the preparation for the final facial veneers (additive wax-up). The use a dif-



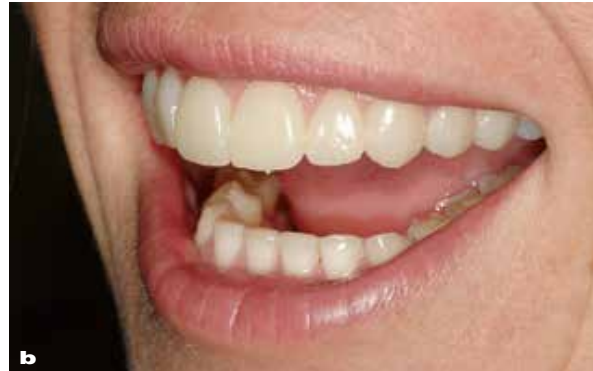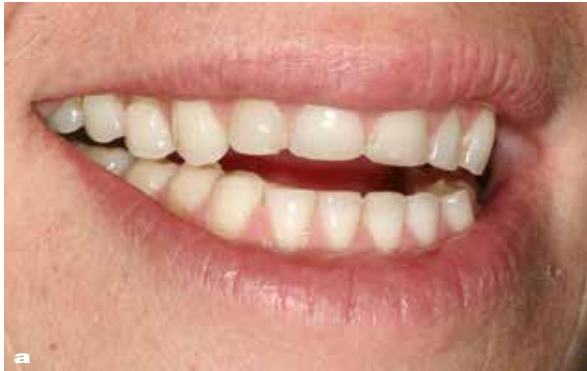**Fig 2a and b** Maxillary vestibular wax-up. Only the incisal edges and the vestibular cusps of the maxillary teeth are reconstructed in wax, where needed. The antagonistic cast is not considered at this stage, since before progressing to the occlusal wax-up, the esthetic occlusal plane should be validated clinically with the patient.



**Fig 3a and b** This simplified wax-up is then used to fabricate a vestibular mock-up. Thanks to the limited wax on the palatal aspect, the mock-up key will be very stable on the teeth, limiting the presence of excesses. Patients could also keep the mock-up and remove it themselves simply by pulling it in the vestibular direction.



**Fig 4a to c** Lack of contrast between the stone and the wax did not allow for the evaluation of the thickness of the future restorations. A silicon index was necessary to see the vestibular space occupied by the wax, which in this specific case was insufficient for a non-invasive approach.



**Fig 5a and b** Maxillary vestibular mock-up. To avoid any occlusal preparation of the maxillary posterior teeth, the additive wax-up lowers the position of the initial occlusal plane, worsening the existing reverse smile. Thus, before waxing the occlusal surfaces of the posterior teeth, it is mandatory to confirm with the patient the choice of longer anterior teeth to harmonize the new occlusal plane.

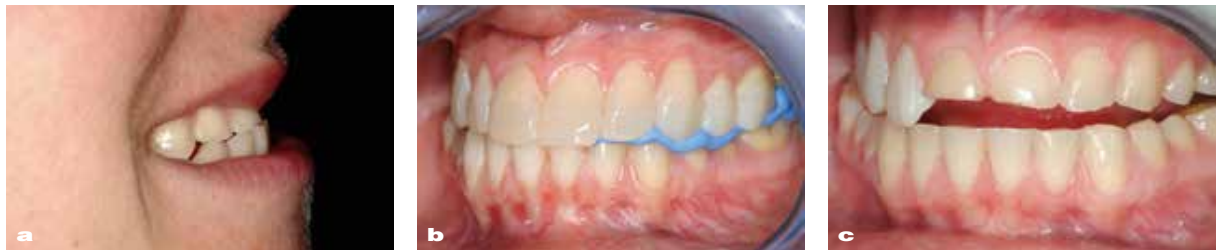ferent color wax to allow the visualization of its thickness is fundamental (Fig 4).

At the completion of *clinical step 1*, while the patient expresses an opinion on the look of the maxillary vestibular mock-up, the clinician should gather information for the restoration of the posterior teeth. In fact, the major goal in this mock-up visit is to validate the esthetic position of the occlusal plane (eg, harmony with the incisal edges), so that the laboratory technician has helpful information on how to share the posterior interocclusal space, which will be obtained with the increase of the VDO (Fig 5).

One of the variants of a classic *clinical step 1* occurs in cases where there is an insufficient horizontal overlap of the maxillary anterior teeth. Generally, to fabricate the maxillary vestibular wax-up, waxing up the opposing arch is not considered, since the increase of the VDO has not yet been decided. However, in case the mandible has a protrusive position, the maxillary vestibular wax-up could be used to also determine the increase of the VDO clinically. In this

case, the laboratory technician would be instructed to lengthen the maxillary anterior teeth until their incisal edges overlap the antagonistic teeth. The incisal edges of the waxed-up teeth should have a minimal horizontal and vertical overlap (at least 1.5 mm), and a minimal thickness (1.5 mm), to guarantee the strength of the final restorations. During the mock-up visit, the clinician, in addition to evaluating the esthetic outcome of the lengthened teeth, may also register the patient's occlusion at the new increase of the VDO by asking the patient to simply bite on the incisal edges of the mock-up, and then inject bite registration material in the posterior sextants (Fig 6).

Another variant to the classic three-step applies in cases affected by initial/moderate dental erosion where the tooth destruction is not sufficiently severe to justify the need for facial veneers. When the vestibular aspect of the maxillary anterior teeth is mostly intact, and the patient can be restored only by means of palatal veneers, a mock-up visit is not necessary, since the incisal edges



**Fig 6a to c** A 23-year-old patient affected by severe dental erosion. The laboratory technician was instructed to also consider the position of the mandibular arch. During the wax-up, the maxillary incisors were lengthened until a minimal overlap with the antagonistic teeth (1.5 mm) was achieved. During *clinical step I*, with the maxillary vestibular mock-up in place, the clinician evaluated whether the length of the mock-up pleased the patient. In addition, the bite was registered by asking the patient to bite on the mock-up while registration material was injected into the posterior spaces.

and the occlusal plane of the final restorations can easily be visualized with the casts and the clinical photographs of the patient's smile. *Step I* (the maxillary vestibular wax-up) is then skipped, and the laboratory technician can directly start the wax-up of the posterior quadrants, reducing the cost and speeding up the therapy (MODIFIED three-step technique).<sup>9</sup>

### Step II

#### The posterior support

The aim of *laboratory step II* is to wax up the posterior teeth at an increased VDO. This wax-up will involve only the occlusal surfaces of the two premolars and the first molars, and will be used to fabricate direct composite restorations by means of transparent keys.

At this stage, the clinician must be prepared to answer three questions:

- How much to increase the VDO.
- How to distribute the posterior inter-occlusal space obtained with the increase of the VDO.

- Which posterior restorations to use during *step II* (direct and/or indirect restorations).

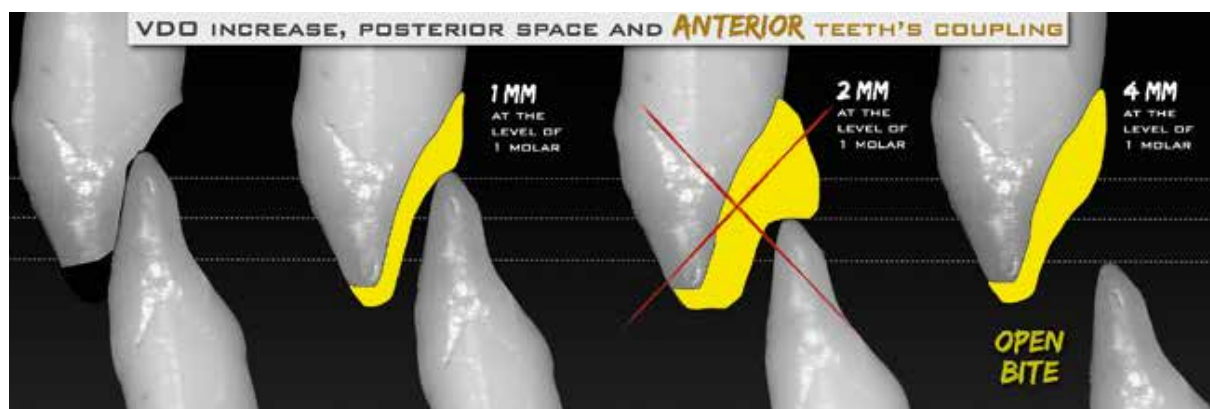
After having established the esthetic occlusal plane in *step I*, in order to complete the occlusal surfaces of the posterior teeth it is necessary to determine the increase of the VDO. As already mentioned, in case of a severely worn dentition, an increase of the VDO is inevitable to reduce the need for substantial tooth preparation in general, and to avoid elective endodontic treatments, in particular at the level of the anterior teeth. Clinicians are generally afraid to increase the VDO, fearing consequences at the level of the temporomandibular joints. On the contrary, the capacity to adapt to the change of the VDO is generally remarkable.<sup>10-14</sup> However, while for the posterior teeth a conspicuous increase of the VDO is always favorable to deliver thicker restorations and avoid tooth preparation, limitations exist in delivering too-bulky anterior restorations to reestablish the contact points.

Consequently, the increase of the VDO is more restricted by the risk of set-



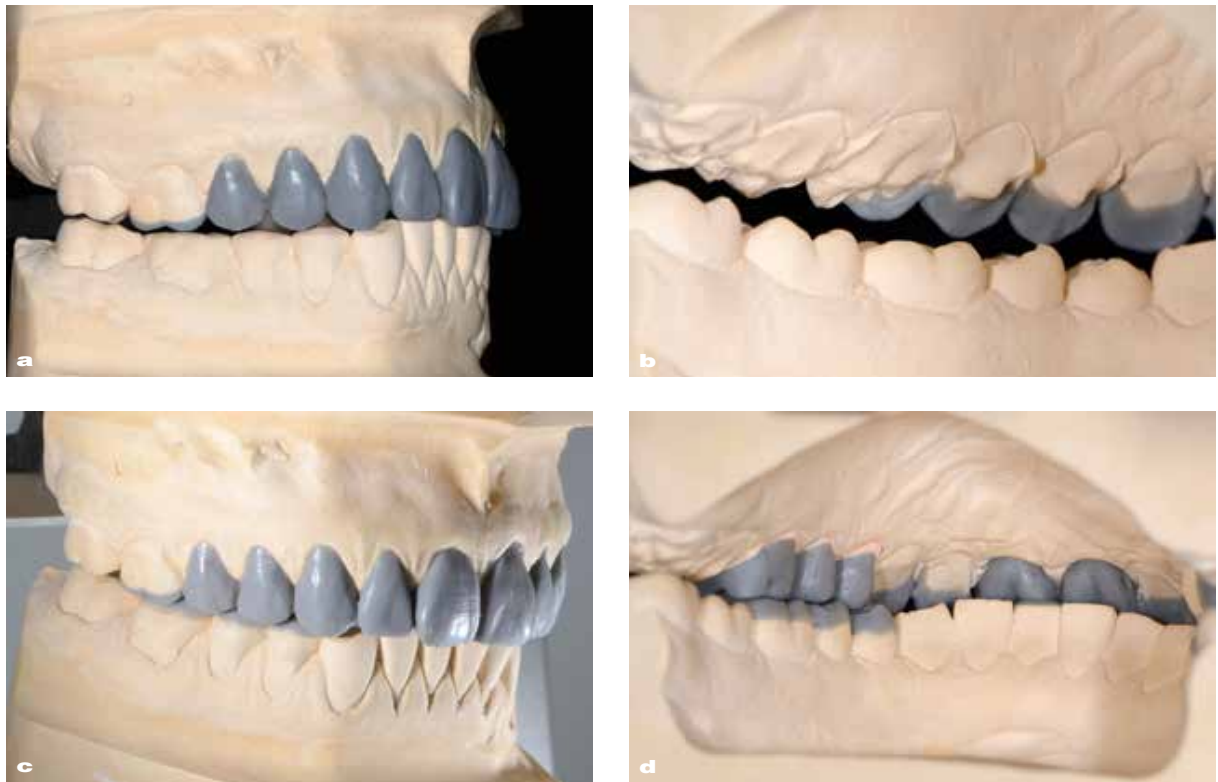
ting the anterior teeth too far apart than by the patient's poor adaptability to the increase of the VDO. Since each patient presents a different scenario, a careful evaluation of the articulated casts should be considered before deciding on the increase of the VDO. The three-step technique suggests first making an arbitrary choice by looking at the initial casts mounted on the articulator. The increase of the VDO should be guided not only by restorative needs, such as the type of restorative material selected (eg, ceramic or composite), but also by occlusal considerations. While deciding on the increase of the VDO, attention should be paid to harmonizing the curve of Spee and correcting the deep bite, especially in erosive patients with a reverse smile and supraerupted mandibular incisors.<sup>15</sup> To flatten the curve of Spee without orthodontic therapy, a significant amount of the space obtained with the increase of the VDO should be given to the mandibular arch, leaving less space available for the maxillary posterior teeth.

There are two extreme clinical choices when considering the increase of the VDO (Fig 7). The first choice is to favor the anterior teeth with a minimal increase of the VDO, which will lead to a rehabilitation with adequate final contact points in the anterior quadrants, but thinner and weaker posterior restorations. In addition, it will be difficult to correct the occlusal plane and/or the deep bite. The second choice is to favor the posterior teeth with a maximum increase of the VDO, which will obtain adequate thickness of the posterior restorations without any tooth preparation. At the same time, it will be possible to harmonize the occlusal plane and improve the deep bite. However, the treatment will lead to the creation of an anterior open bite, which cannot be corrected only by means of palatal veneers. With the second choice, orthodontic therapy could be considered afterwards to restore the anterior contacts. The least-favorable solution with the second choice is to leave the patient with an anterior open bite. In this unstable occlusal situation,

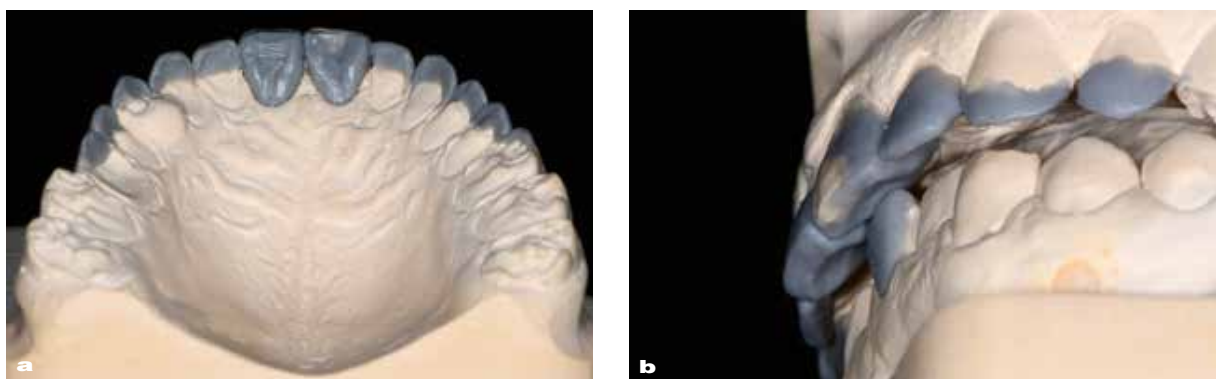


**Fig 7** The increase of the VDO should be related to the anterior and posterior teeth. While for the posterior restorations a conspicuous increase is always auspicious, for the anterior teeth there is a limitation to increasing the size of their palatal aspect.

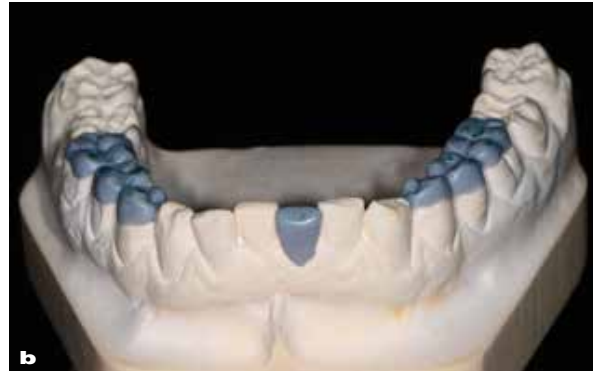
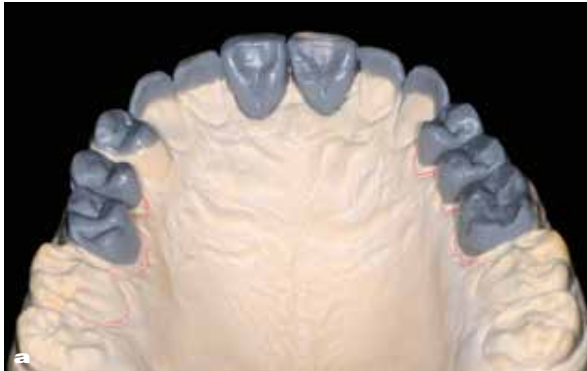


**Fig 8a to d** Progression of the wax-up to the posterior teeth. The esthetic occlusal plane had indicated how much of the interocclusal posterior space could be given to the maxillary posterior teeth. To know how much is left for the mandibular teeth, the increase of the VDO should be determined first. In this patient, the ANTERIOR stop was touching the antagonistic teeth, and the posterior space obtained was considered sufficient to deliver thick-enough posterior restorations.



**Fig 9a and b** Maxillary vestibular wax-up and ANTERIOR stop. Thanks to the presence of the ANTERIOR stop, the posterior teeth were set apart. Their separation indicated the maximum possible increase of the VDO, which still allowed for obtaining anterior contacts. The clinician should now decide if the interocclusal space is sufficient for the posterior restorations selected. Note that the ANTERIOR stop in this patient also included a mandibular incisor.



**Fig 10a and b** Progression of the wax-up shown in Fig 9, after taking the decision on the amount of increase of the VDO.

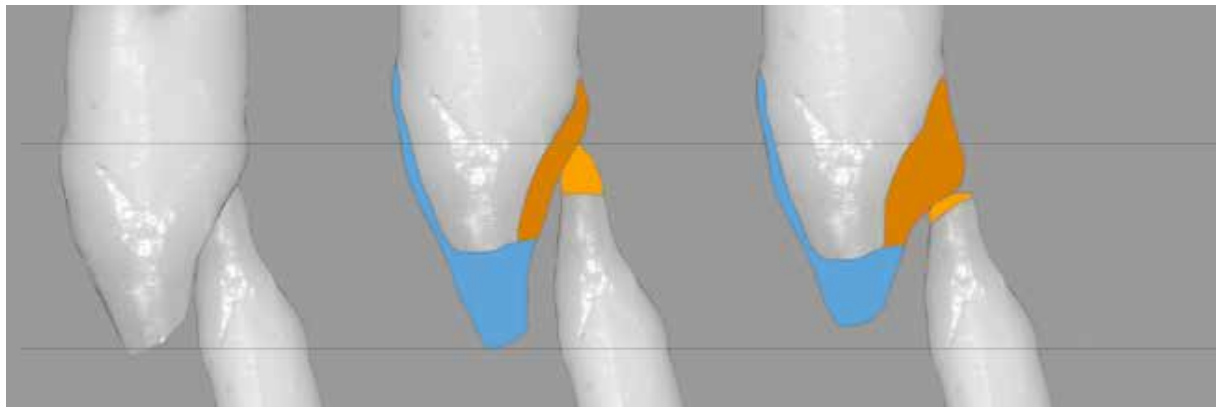
a Michigan occlusal splint should be worn every night to stabilize the anterior contact and avoid supraeruption. Since the anterior teeth's coupling is the limiting factor in the increase of the VDO, the laboratory technician should provide an ANTERIOR stop by reconstructing in wax only the palatal aspect of the two central incisors to the thickest clinically acceptable shape.

Only two central incisors are necessary to fabricate the ANTERIOR stop, since leaving the surfaces of the adjacent teeth free of wax allows for a better judgment on the clinical acceptability of the bulkier palatal surfaces. With the models mounted on the articulator, the clinician can visualize the interocclusal space obtained in the posterior sextants when the casts touch at the level of the reconstructed central incisors, since this represents the maximum amount of the VDO possible to still reestablish anterior contacts. The clinician should then decide if this increase of the VDO is sufficient for the restorative needs of the posterior teeth or not, and make the clinical choice of favoring either the anterior or the posterior teeth (Figs 8 to 10).

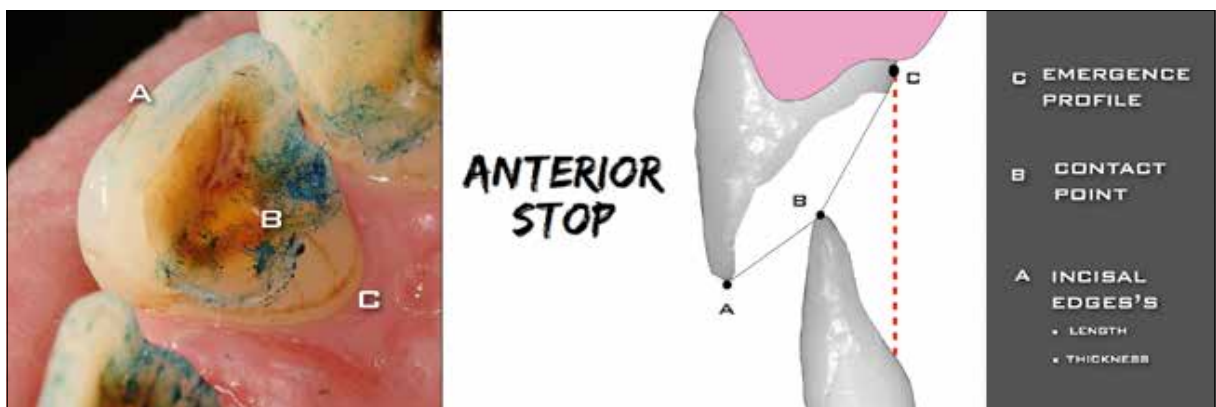
If the mandibular anterior teeth present exposed dentin, they should also be included in the treatment and in the ANTERIOR stop. For the mandibular (as well as the maxillary) anterior teeth, only a few strategic teeth should be waxed up (ie, the most vestibular ones), to better visualize the clinical outcome. Thanks to this partial wax-up, malpositioned teeth can be better identified, and the need for orthodontic therapy may be advocated. While reconstructing damaged mandibular teeth in wax, the laboratory technician should be careful not to lengthen their incisal edges excessively, since these teeth often already present a supraerupted position. In addition, lengthening these teeth in the incisal direction will worsen the curve of Spee and the vertical overlap (deep bite) (Fig 11).

To fabricate an ANTERIOR stop, three points should be identified:

- A – Incisal edge of the final restoration.
- B – New contact point with the antagonistic tooth after an increase of the VDO.
- C – Most cervical margin of the final restoration.



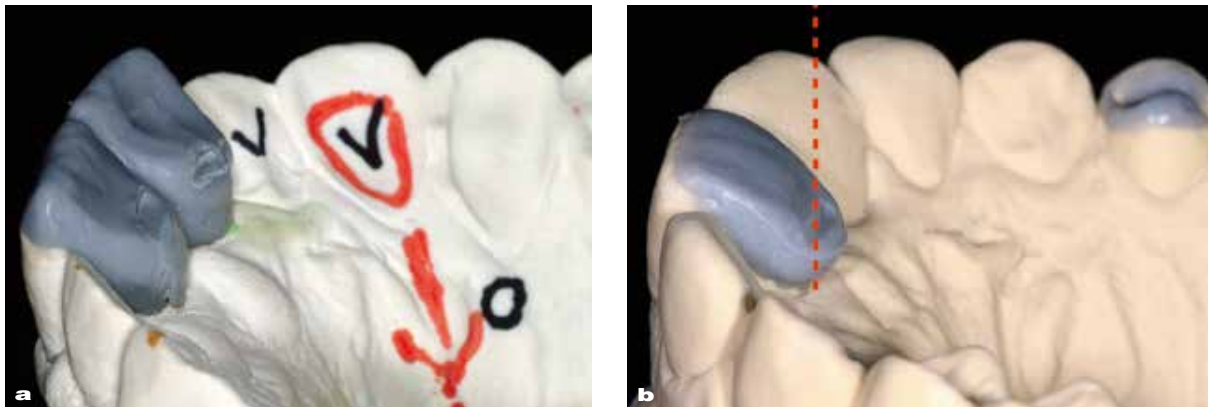
**Fig 11** Restoration of the anterior teeth and deep bite. To avoid worsening the deep bite, the clinician and laboratory technician should resist the temptation to excessively lengthen the incisal edges of both the maxillary and mandibular teeth. In particular, the mandibular incisors are often supraerupted, so instead of lengthening their incisal edges, the contact point should be reached by thickening the palatal aspect of their antagonistic teeth.



**Fig 12** Three points could be identified in an ANTERIOR stop. A decision on the position of the B point (new contact point at the increase of the VDO) should involve the clinician, since the final shape may be bulkier than a natural tooth, to allow for a larger increase of the VDO. The clinician should determine whether the new shape is clinically acceptable to the patient.

The union of these three points defines the palatal shape of the maxillary palatal restorations. The junction between B and C should be as straight as possible to avoid phonetic impairments and plaque accumulation (cleansability), but to still guarantee support to the occlusal

contact (mechanical strength) (Fig 12). It is recommended that the palatal wax-up be kept inside a vertical line passing through the C point (the C line), placed on a frontal plane. This line defines the most palatal limit where the occlusal contact (B point) could be placed (Fig 13).

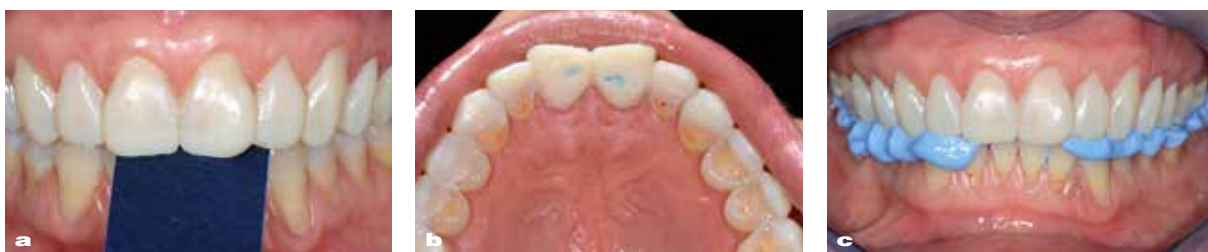

**Fig 13 and b** Incorrect ANTERIOR stops. In both cases, the B point was more palatal than the C line, and this shape for the final restorations would not have been tolerated by the patient. With just this minimal wax-up, the clinician has gained valuable information on the increase of the VDO and the reestablishment of the anterior contact points.

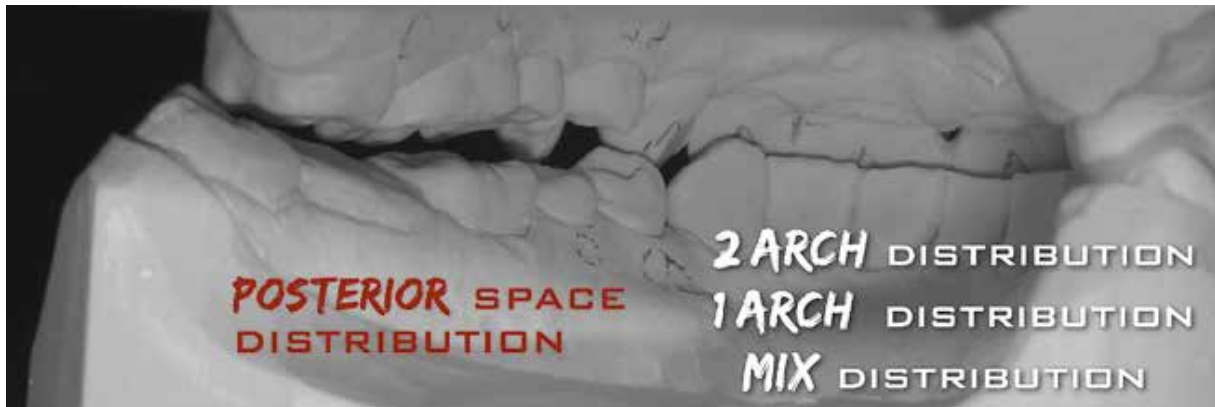The three-step technique recommends the articulation of the models in MIP. However, for more complex cases (eg, deviated mandible), it is possible to reregister the position of the mandible at the increased VDO during the mock-up visit, thanks to the presence of the ANTERIOR stop, which could also be used as an anterior jig. While the patient is biting on the ANTERIOR stop, the interarch posterior space is filled with registration material. The mandibular cast can then be remounted, since the occlusal aspect of the posterior teeth is partially not covered by the mock-up, and the occlusal

bite registrations could be adapted on the models (Fig 14).

While deciding on the increase of the VDO, the clinician should also consider how to distribute the obtained interocclusal space among the posterior teeth. This decision will mostly be based on the presence of exposed dentin (eg, teeth to be restored), and the finances of the patient. The authors believe that it is also important to flatten the occlusal plane and reduce the deep bite whenever possible to promote more freedom to the lateral excursions of the mandible.<sup>15</sup>



**Fig 14a to c** An ANTERIOR stop could become an anterior jig during the mock-up visit to rearticulate the casts at a increased VDO (case completed with Dr. C Damardji).



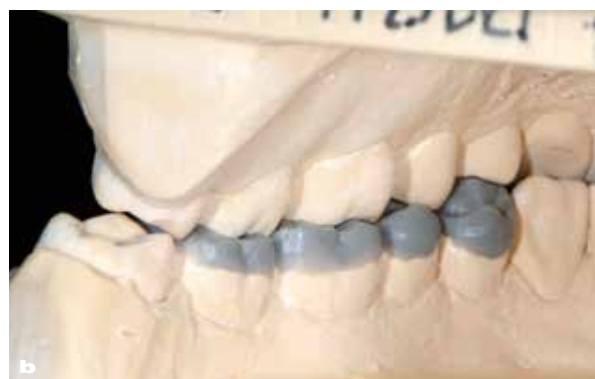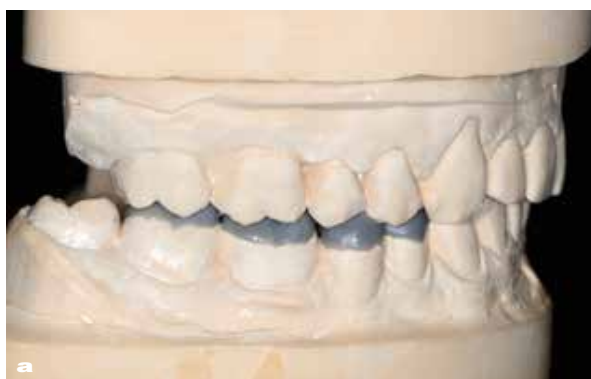**Fig 15** The best view to analyze articulated casts is from the palatal/lingual aspect. While laboratory technicians are familiar with this view, clinicians are not, since it is impossible clinically. From this view it is easier to visualize the occlusal plane, the curve of Spee, and the supraerupted mandibular anterior teeth.

The posterior interocclusal space could be shared in three different ways: 1) one-arch distribution; 2) two-arch distribution; 3) mixed distribution (Fig 15).

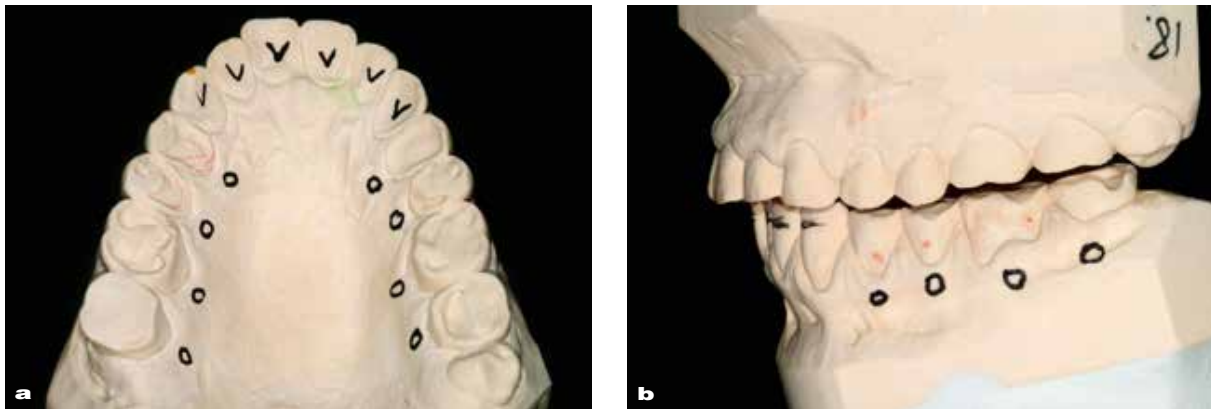
*One-arch distribution*

With this option, the space is given to only one arch (mandibular or maxillary). The advantage of this option is the reduction in the overall cost of treatment, since only one arch is restored. In addition, the space obtained by the

increase of the VDO will not be shared among antagonistic teeth. Consequently, the increase of the VDO could be kept smaller, and the open bite corrected more easily by means of palatal veneers. Unfortunately, this option is not always possible due to clinical limitations. For example, the posterior teeth of the unrestored arch should be intact (no dentin exposure), and the existing occlusal plane of the antagonistic teeth should be correct (Fig 16).



**Fig 16a and b** One-arch distribution. The increase of the VDO required to repair the incisal edges was minimal. Since the maxillary posterior teeth were intact, it was decided to increase the VDO, restoring only the antagonistic mandibular teeth.



**Fig 17a and b** Two-arch distribution. A moderate to severe case of dental erosion. Both the arches presented teeth with exposed dentin, so a two-arch distribution was necessary, requiring more space at the level of the posterior teeth.

#### *Two-arch distribution*

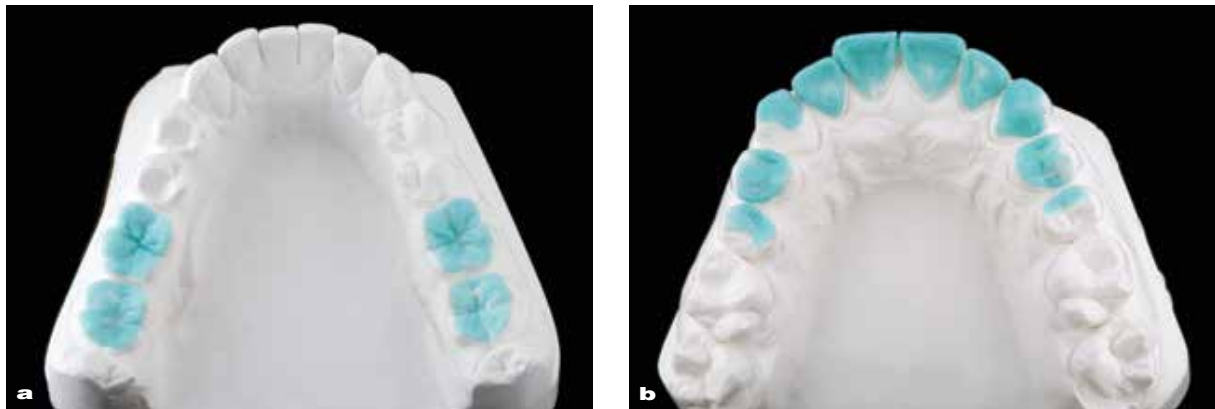
This is the most common situation, especially in the case of severe dental wear, since unfortunately the posterior teeth of both the arches present exposed dentin and need to be restored. The advantage of this option is the possibility of changing the position of the occlusal plane by modifying both the occlusal surface of the maxillary and mandibular posterior teeth. One disadvantage is the cost, since the patient has to pay for a full-mouth rehabilitation, with the restoration of all the posterior teeth. Another disadvantage is the necessity to share the interocclusal space obtained with the increase of the VDO. For example, if 2 mm is available at the level of the first molar, the two antagonistic onlays sharing the available space equally will only have a 1-mm thickness, which may not be strong enough, especially in patients with parafunctional habits (Fig 17).

#### *Mixed distribution*

This distribution means that both the maxillary and mandibular posterior teeth

will be restored, but not all of them. This is often the case when there is an irregular occlusal plane, with supraeruption of some posterior teeth. To achieve a correct occlusal plane, the supraerupted teeth will not be restored, if of course their occlusal surface is intact. The advantage of this option is that it costs less and has a shorter clinical time compared to the two-arch distribution (Fig 18).

Before the laboratory technician starts the wax-up of the posterior teeth, the clinician should also have an idea about which type of restorations will be delivered during *step II* – provisional and/or final – so that the wax-up can be modified accordingly. In this article, only the wax-up modifications in case of fabrication of provisional restorations are discussed. When the dentition is particularly compromised and/or a mandibular deviation is present, it is preferable during *step II* to deliver provisional posterior composite restorations, fabricated directly in the mouth by means of transparent keys. This treatment is comparable to an occlusal bite bonded for 24 h in



**Fig 18a and b** Mixed distribution. In this early case of dental erosion, the increase of the VDO was minimal and necessary mostly to reinforce the thin incisal edges. To reduce the number of teeth to be restored and to avoid sharing the limited posterior interarch space, only the mandibular molars and the maxillary premolars were restored. It was possible to not include the remaining posterior teeth in the rehabilitation, since they did not present dentin exposure. Note that the wax-up of the palatal aspect of all the maxillary teeth was not necessary. The ANTERIOR stop could be done with only one or both central incisors.

the mouth (therapeutic white bite). This is also the fastest treatment to restore multiple teeth at the same time (eg, in a two-arch distribution) for patients who do not have time or cannot tolerate long appointments.

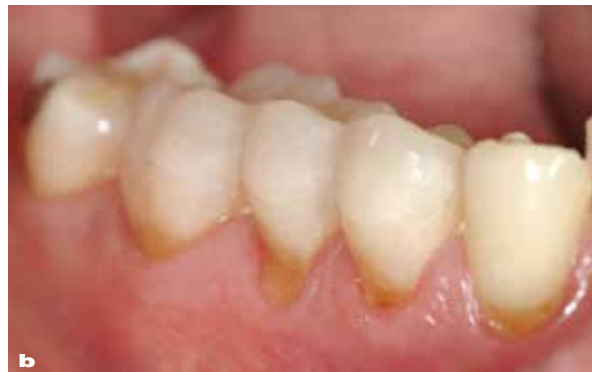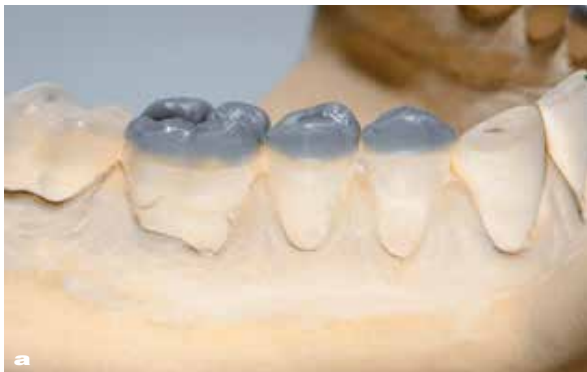Following the three-step technique, these provisional restorations will be replaced after the rehabilitation of the anterior quadrants by the final restorations. When the wax-up of the posterior teeth is used for the fabrication of the provisional restorations, it should be modified at four levels before the fabrication of the transparent keys:

- 1) interproximal areas;
- 2) mesial and distal stops;
- 3) occlusal embrasures (marginal ridges); and
- 4) vestibular/palatal surface (one-third cervical).

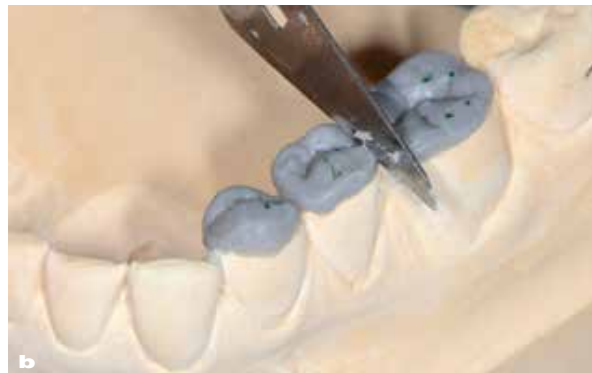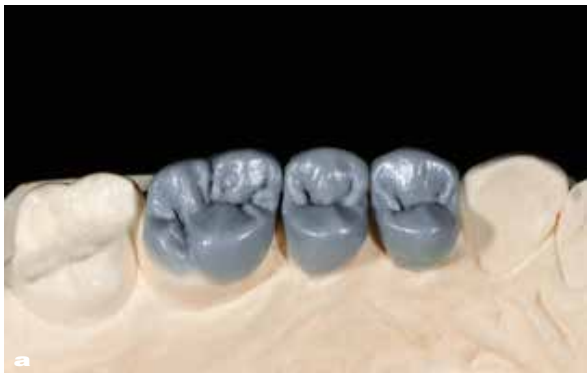In general, the wax should be kept to a minimum and placed only on the occlusal surfaces where the contact points of

the white bite will be. The remaining wax should be removed before the fabrication of the keys to reduce the size of the provisional composite restorations and facilitate their future removal. In addition, the interproximal areas should be clean of excess wax, to reduce the risk of interproximal excesses during the fabrication of the composite restorations. A mesial and a distal stop should always be identified and left waxfree, to promote a better sitting of the transparent keys (ie, less occlusal adjustments). Damaged vestibular and/or palatal surfaces may also represent a dilemma during the wax-up. The laboratory technician should resist the temptation of fully reconstructing in wax these damaged surfaces, since the clinician does not need to fabricate the provisional composite so close to the cervical aspect of the teeth (high risk of excess) (Fig 19).

The only reason to extend the wax-up to the cervical aspect is if the supporting cusps are very compromised (eg,



**Fig 19a and b** For a white bite, the wax should be limited to the occlusal surfaces only, even when the teeth are not intact in the cervical third. This will guarantee better bonding conditions and easier removal of the excesses.



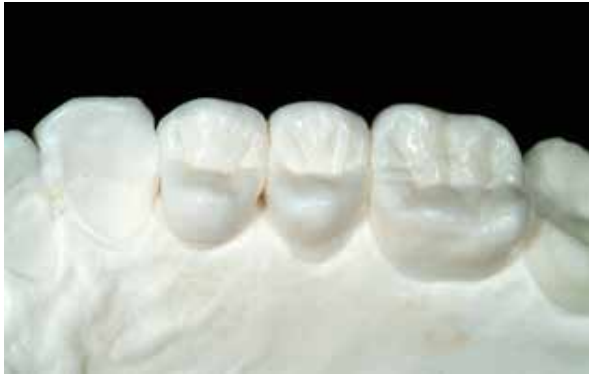**Fig 20a and b** The posterior wax-up to fabricate the transparent keys should be very precise at the level of the embrasures. Any excess of wax will lead to an excess of composite in the mouth. The marginal ridges could be weakened with a scalpel to promote the opening of the contact points between the direct restorations during mastication.

palatal maxillary cusps), and the occlusal contacts of the white bite need to be reinforced (ie, avoid shear failure). One of the limits of the white bite is the closed interproximal contact points. To try to favor their opening during function, the occlusal embrasures of the wax-up could be weakened by accentuating the separation of the waxed-up marginal ridges with a scalpel (Fig 20). Finally, it is worth remembering to always use a different color wax, since

the clinician will use the contrast with the stone to get an idea of how much composite should be placed in the transparent keys (Fig 21).

At the end of *clinical step II*, patients will present a stable posterior support at an increased VDO and an anterior open bite. Thanks to this anterior space, the maxillary anterior teeth will then be restored without any tooth preparation (maximum tooth preservation) by means of palatal veneers (*step III*). To move to





**Fig 21** The use of a similar color between the wax and the cast makes it very difficult to see the limits of the wax and its thickness. Note that the maxillary canine is not free of wax, and if this is not removed, the transparent key will not have its mesial stop.

the next step, new impressions, an anterior bite registration in MIP, and a face-bow are needed.

### Step III

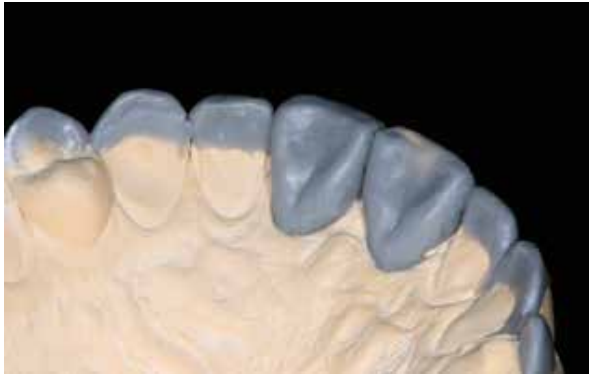#### The anterior contacts

In *step III*, the laboratory technician will recreate in wax the palatal surfaces of the maxillary anterior teeth before fabricating the palatal veneers. The shape of the two central incisors was already proposed with the ANTERIOR stop, and confirmed or changed by the clinician (Fig 22).

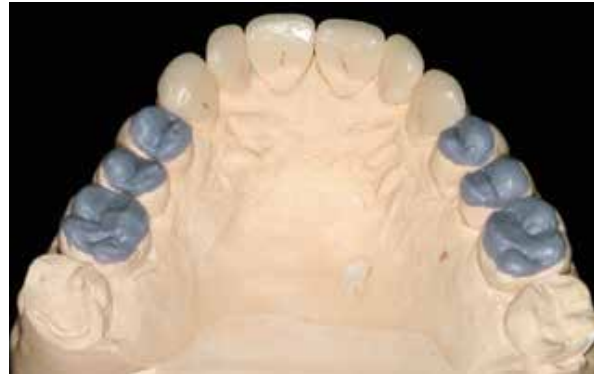As previously mentioned, one of the advantages of the three-step technique is the possibility of evaluating and, if necessary, correcting the outcome of previous steps. The increase of the VDO, obtained during *step II*, could be

modified during *step III*. In case the laboratory technician realizes that the clinical increase of the VDO was excessive to reestablish the anterior contacts by means of palatal veneers, he/she can progress with the fabrication of the final anterior restorations to the ideal shape, which will have no contacts with the antagonistic teeth. The clinician will then bond these restorations and adjust the occlusion on the posterior teeth until the anterior teeth are in contact (decrease of the VDO). It is also possible to correct the opposite situation (increase of the VDO). In this scenario, the VDO will be increased on the articulator by adding wax on the posterior teeth, and the palatal veneers will be fabricated accordingly. Once bonded on the palatal veneers, as expected, the posterior teeth will no longer be in contact. To reestablish the posterior support, simple direct composite will be delivered by adding material on the previously roughened surfaces of the pre-existing contact points. To facilitate this second option, the direct composite restorations should be made in only one arch. If major increments of the VDO are necessary, new transparent keys could be used to speed up the treatment (Fig 23).

Several authors have set fundamental guidelines for the reconstruction of the palatal surfaces of the maxillary anterior teeth, especially considering the envelope of function.<sup>16-25</sup> However, following the three-step technique, the shape of the maxillary anterior final restorations is strongly dictated, not only by restoring the damaged palatal aspect, but also by the need to establish the anterior contacts after the increase of the VDO. To achieve these contacts,



**Fig 22** Waxing up the central incisors to fabricate the ANTERIOR stop allows the laboratory technician to discuss the shape of the future palatal veneers. At this stage, the clinician can ask for modifications or accept the proposed form.



**Fig 23** In this case, the increase of the VDO obtained with the white bite was not sufficient. Instead of rescheduling the patient, with the same impression for the palatal veneers, the laboratory technician waxed up the occlusal surfaces of the maxillary teeth and fabricated the palatal veneers at the increased VDO. Two transparent keys were used to increase the VDO before bonding the veneers.

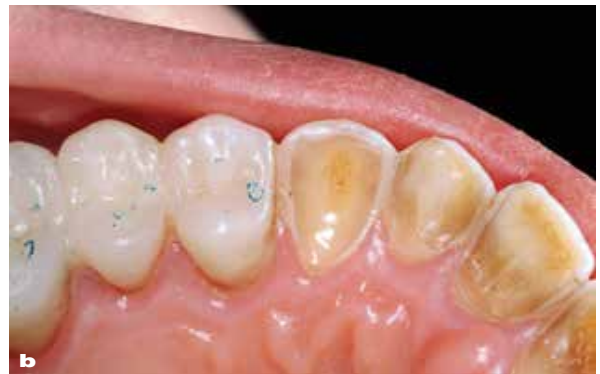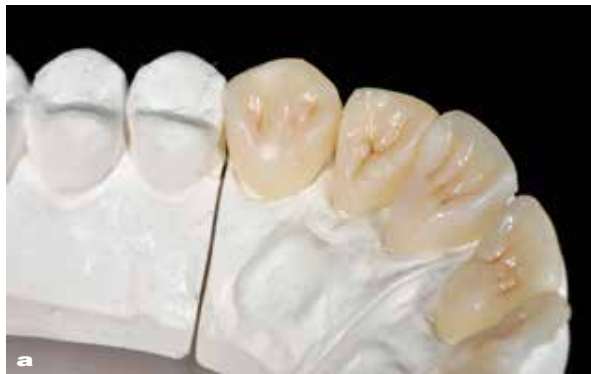there is no hesitation to restore teeth to a larger size than the natural dentition. In addition, clinicians often have to face and solve dental/skeletal discrepancies – improved or aggravated by the increase of the VDO – by using restorative means only, since this type of patient accepts the therapy because of its simplicity (and rapidity), and frequently refuses orthodontic therapy and even more frequently, orthognathic surgery. Therefore, the laboratory technician will rarely be inspired by the natural dentition for the anterior region of the mouth, and will recreate the perfect shape and ideal contact points.

Overall, the restored teeth will always look wider in an anterior–posterior direction than the natural dentition, and laboratory technicians should not feel uncomfortable about delivering restorations with an unusual shape. Even though it is expected that the palatal

aspect of these restored teeth should not resemble the intact teeth, appearing thicker even at the incisal edges, there are limitations to how much the size can be increased.

There are six major objectives during *step III* (fabrication of the palatal veneers):

- Re-establish anterior contacts points (B points), unless decided otherwise.
- Supported B points (eg, not on surfaces that are too inclined).
- BC line straight (for cleansability and phonetics).
- Smooth palatal surfaces (no excessive anatomy).
- Maximum effort to correct or not aggravate deep bite (minimum lengthening of both the incisal edges of maxillary and mandibular teeth).
- No steep anterior guidance (open incisal angle).



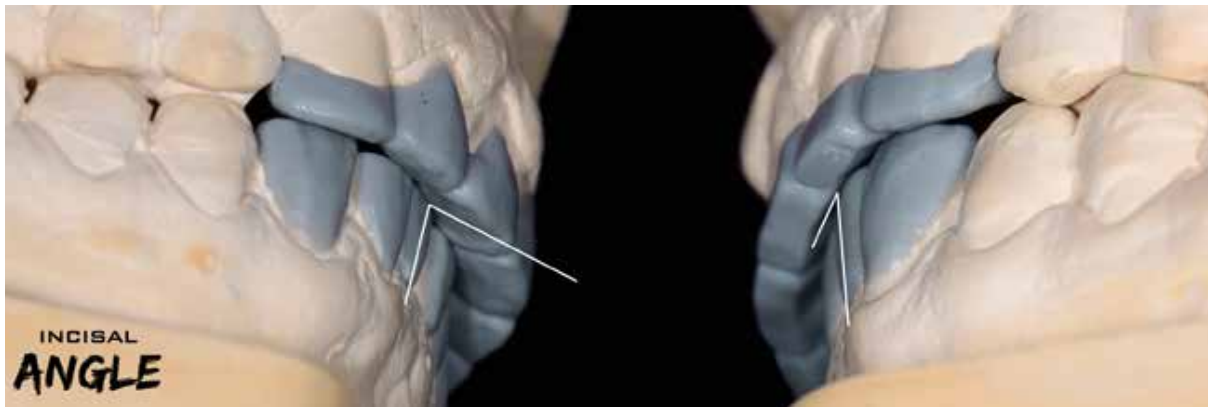
**Fig 24a and b** Palatal veneers with a palatal anatomy that is too accentuated, occupying space for the tongue without any functional purpose. In addition, these veneers could be very uncomfortable for patients who are accustomed to a concave shape of eroded teeth.

While defining the maximum thickness tolerated by each patient, laboratory technicians should bear in mind that patients affected by dental erosion are used to having very flat/concave palatal surfaces, and that they have adapted the tongue to speak even with a conspicuous loss of tooth structure, since this loss has happened progressively at a very slow rate.

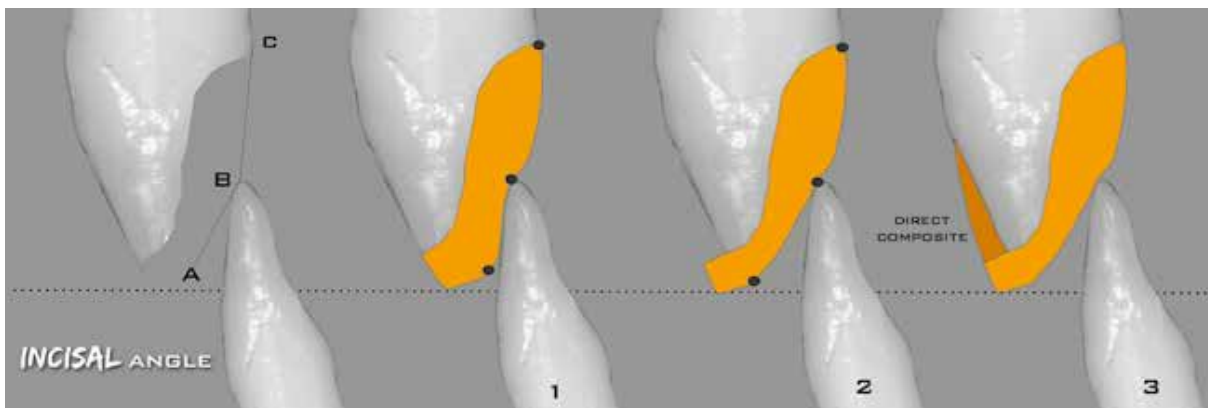
Occupying the tongue space with bulky palatal veneers all at once will be immediately considered uncomfortable by the patient, especially because it would cause the impairment of the pronunciation of some letters (eg, D-T sounds). In time, the tongue will eventually adjust, but there will be patients who will struggle for longer, and who may panic in the meantime. As a general rule, since the final shape will be bigger, the size of the palatal surfaces should be kept flat in the areas cervically to the B point (straight BC line). Complicated occlusal anatomy should be avoided, such as very deep palatal

grooves and/or pronounced cingula. In addition, not only is more effort required, but the surfaces of the final restorations will be more difficult to polish, and the irregular texture will be very uncomfortable for the patient's tongue (Fig 24).

During the fabrication of the ANTERIOR stop, the laboratory technician focused only on static occlusal contacts, mostly analyzing the shape of the palatal surface between the B and C points for cleansability and problems with phonetics. In this *laboratory step III*, the surface, comprised between the B and A points, will also be considered, since this is the area involved in the eccentric movements (anterior guidance). Several authors have given guidelines to correlate the condylar inclinations with the steepness of the anterior guidance, and it is not the objective of this article to analyze the validity of the different methods to achieve a correct occlusal scheme, especially when there is no evidence to support the superiority of one method over the others.<sup>26</sup>



**Fig 25** Incisal angle. This angle is defined by the AB line (from the contact point to the incisal edge) and the facial surface of the antagonistic tooth. In the case on the right, the incisal edges are too thick. Reducing their volume without compromising the mechanical strength of the future palatal veneers will open the incisal angle and promote the freedom of the mandible in its functional movements.



**Fig 26** To open the incisal angle (1), the A point is moved more vestibularly (2). The palatal veneer will stop with a step (2), which will be filled by the composite used during the bonding procedure to smooth the transition and improve the shade matching with the remaining tooth structure (3).

As a general rule, since a rigid articulator cannot duplicate the sophisticated mandibular movement, the three-step technique promotes the use of the patient as the “final articulator” to test the occlusion. Consequently, occlusal adjustments in the mouth will always be required and expected.<sup>21</sup> The use of composite for the therapeutic bite and the

palatal veneers facilitates this task. The eccentric movements are simply tested with the patient sitting upright, not anesthetized, and chewing a small piece of gum. It is very surprising how patients know exactly which are the interferences during chewing when they are not anesthetized. Following the patient’s request, group function is often the pre-



ferred choice over canine guidance, especially in horizontal chewers.<sup>15</sup> Since the eccentric movements will be tested in the mouth, the laboratory technician is instructed to only reduce the steepness of the incisal guidance, adopting an arbitrary condylar inclination of 30 degrees.

One method to reduce the steepness is to resist the temptation of rejuvenating the smile, and to lengthen the teeth indiscriminately in every patient (without considering the initial status and/or the presence of parafunctional habits). To help visualize the steepness of the anterior guidance, an incisal angle could also be identified by tracing the AB line and intercepting it with the vestibular surface of the mandibular antagonistic tooth (incisal angle) (Fig 25). To open the incisal angle, the laboratory technician may also reduce the thickness and/or move the position of the incisal edges facially. The palatal veneers will then join the vestibular surface with a step, which will be filled with the hybrid composite used to bond the veneers. In this manner, not only will the anterior guidance be less steep, but the color match will also be improved, without the need for a chamfer preparation (Fig 26).

### Conclusion

A full-mouth wax-up is considered a necessary step for the correct treatment planning of a full-mouth rehabilitation. Unfortunately, when asking for a comprehensive wax-up, clinicians delegate important decisions to their laboratory

technicians, who are not experienced/knowledgeable enough to choose from the different options and consider their clinical implications. As a result, the risk of remakes and misunderstandings increases. The simplified approach that has been developed – the three-step technique – promotes an active interaction between the clinician and the laboratory technician through the progressive development of the wax-up. This technique fragments the wax-up of the full-mouth rehabilitation into stages, and allows the clinician to clinically validate the laboratory technician's choices. Thanks to the simplicity of the three-step technique, critical parameters such as the incisal edges, the occlusal plane, and the VDO can be correctly evaluated, and the final treatment plan is visualized progressively with the progression of the wax-up and the gathering of more clinical information.

### Acknowledgments

The authors would like to thank Professor Irena Sailer for believing in and supporting the concept of the three-step technique at the University of Geneva. Thanks to all the laboratory technicians who have contributed with their passionate work to the development of the three-step technique and the creation of this article, being: Sylvain Carciofo, Alwin Schonenberger, Patrick Schnider, Pascal Muller, August Bruguera, Serge Erpen, Vincent Locultre, Giuseppe Dolce, Romeo Pascetta, and Giuseppe Romeo.



## References

1. Vailati F, Bruguera A, Belser U. Minimally invasive treatment of initial dental erosion using pressed lithium disilicate glass-ceramic restorations: a case report. *QDT* 2012;1–14.
2. Grütter L, Vailati F. Full-mouth adhesive rehabilitation in case of severe dental erosion, a minimally invasive approach following the 3-step technique. *Eur J Esthet Dent* 2013;8:358–375.
3. Vailati F, Belser UC. Palatal and facial veneers to treat severe dental erosion: a case report following the three-step technique and the sandwich approach. *Eur J Esthet Dent* 2011;6:268–278.
4. Vailati F, Vaglio G, Belser UC. Full-mouth minimally invasive adhesive rehabilitation to treat severe dental erosion: a case report. *J Adhes Dent* 2012;14:83–92.
5. Vailati F, Belser UC. Full-mouth adhesive rehabilitation of a severely eroded dentition: the three-step technique. Part 3. *Eur J Esthet Dent* 2008;3:236–257.
6. Vailati F, Belser UC. Full-mouth adhesive rehabilitation of a severely eroded dentition: the three-step technique. Part 2. *Eur J Esthet Dent* 2008;3:128–146.
7. Vailati F, Belser UC. Full-mouth adhesive rehabilitation of a severely eroded dentition: the three-step technique. Part 1. *Eur J Esthet Dent* 2008;3:30–44.
8. Magne P, Belser UC. Novel porcelain laminate preparation approach driven by a diagnostic mock-up. *J Esthet Restor Dent* 2004;16:7–16.
9. Vailati F, Carciofo S. CAD/CAM monolithic restorations and full-mouth rehabilitation to restore a patient with a past history of bulimia: the modified three-step technique. *Int J Esthet Dent* 2016;11:36–56.
10. Abduo J. Safety of increasing vertical dimension of occlusion: a systematic review. *Quintessence Int* 2012;43:369–380.
11. Walther W. Determinants of a healthy aging dentition: maximum number of bilateral centric stops and optimum vertical dimension of occlusion. *Int J Prosthodont* 2003;16(suppl):77–79.
12. Gross MD, Ormianer Z. A preliminary study on the effect of occlusal vertical dimension increase on mandibular postural rest position. *Int J Prosthodont* 1994;7:216–226.
13. Kohno S, Bando E. Functional adaptation of masticatory muscles as a result of large increases in the vertical occlusion [In German]. *Dtsch Zahnärztl Z* 1983;38:759–764.
14. Carlsson GE, Ingervall B, Kocak G. Effect of increasing vertical dimension on the masticatory system in subjects with natural teeth. *J Prosthet Dent* 1979 Mar;41:284–289.
15. Planas P. *Réhabilitation neuro-occlusale RNO*, ed 2, Group Liaisons, 2006.
16. Lundeen HC, Shryock EF, Gibbs CH. An evaluation of mandibular border movements: their character and significance. *J Prosthet Dent* 1978;40:442–452.
17. Celenza FV. The centric position: replacement and character. *J Prosthet Dent* 1973;30:591–598.
18. Borgh O, Posselt U. Hinge axis registration: experiments on the articulator. *J Prosthet Dent* 1958;8:35–40.
19. Gracis S. Clinical considerations and rationale for the use of simplified instrumentation in occlusal rehabilitation. Part 1: Mounting of the models on the articulator. *Int J Periodontics Restorative Dent* 2003;23:57–67.
20. Gracis S. Clinical considerations and rationale for the use of simplified instrumentation in occlusal rehabilitation. Part 2: setting of the articulator and occlusal optimization. *Int J Periodontics Restorative Dent* 2003;23:139–145.
21. Wiskott HW, Belser UC. A rationale for a simplified occlusal design in restorative dentistry: historical review and clinical guidelines. *J Prosthet Dent* 1995;73:169–183.
22. Dawson P. *Evaluation, Diagnosis, and Treatment of Occlusal Problems*, ed 2. St Louis: Mosby, 1989:206–237.
23. Hobo S. Formula for adjusting the horizontal condylar path of the semiadjustable articulator with interocclusal records. Part II: Practical evaluations. *J Prosthet Dent* 1986;55:582–588.
24. Hobo S. Formula for adjusting the horizontal condylar path of the semiadjustable articulator with interocclusal records. Part I: Correlation between the immediate side shift, the progressive side shift and the Bennett angle. *J Prosthet Dent* 1986;55:422–426.
25. Wiskott HWA (ed). *Fixed Prosthodontics, Principles and Clinics*. London: Quintessence, 2011.
26. Koyano K, Tsukiyama Y, Kuwatsuru R. Rehabilitation of occlusion – science or art? *J Oral Rehabil* 2012;39:513–521.